Indian Heart Journal 73 (2021) 149–155

Contents lists available at ScienceDirect

Indian Heart Journal

journal homepage: www.elsevier.com/locate/ihj

Review Article

# Algorithms for challenging scenarios encountered in transradial intervention

Abhishek C. Sawant [a], David G. Rizik [b], Sunil V. Rao [c], Ashish Pershad [a, *]

[a] Banner University Medical Center, Phoenix, AZ, USA
[b] HonorHealth and the Scottsdale-Lincoln Health Network, Scottsdale, AZ, USA
[c] Division of Cardiology, Duke Clinical Research Institute, Duke University, Durham, NC, USA

ARTICLE INFO

*Article history:*
Received 29 June 2020
Accepted 10 September 2020
Available online 18 September 2020

*Keywords:*
Transradial intervention
Vascular access
Algorithms
Challenges
Complications

ABSTRACT

Transradial intervention (TRI) was first introduced by Lucien Campeau in 1989 and since then has created a lasting impact in the field of interventional cardiology. Several studies have demonstrated that TRI is associated with fewer vascular site complications, offer earlier ambulation and greater post-procedural comfort. Patients presenting with ST Segment Elevation Myocardial Infarction (STEMI) have experienced survival benefit and higher quality-of-life metrics as well with TRI. While both the updated scientific statement by the American Heart Association and the 2017 European Society of Cardiology guidelines recommend a "radial first" approach there appears to be a lag in physicians adapting TRI as the preferred vascular access. We present a review focusing on identification and management of TRA related challenges and complications using a systematic algorithmic approach.
© 2020 Published by Elsevier B.V. on behalf of Cardiological Society of India. This is an open access article under the CC BY-NC-ND license (http://creativecommons.org/licenses/by-nc-nd/4.0/).

## 1. Introduction

Transradial intervention (TRI) has revolutionized interventional cardiology. TRI is associated with fewer access site complications, offers early ambulation, and greater comfort to patients after the procedure.[1–3] In patients presenting with ST Segment Elevation Myocardial Infarction (STEMI), TRI has been associated with lower mortality.[4–6]

The 2017 European Society of Cardiology guidelines endorse radial access as a Class I (level of evidence A) recommendation as the access strategy for cardiac catheterization.[7] However, a steep learning curve has resulted in US physicians being less enthusiastic in adopting TRI as compared to their colleagues from around the world. While an algorithmic approach for trouble shooting technical challenges in other arenas of interventional cardiology like chronic total occlusion intervention has been previously published, such an algorithmic approach for technical challenges in TRI has not been previously published.[8] To address this gap in the literature, we designed a review focusing on algorithmic approaches to challenges in TRI.

## 2. Radial artery anatomy

The radial artery arises from the brachial artery and runs along the lateral aspect of the forearm. As shown in Fig. 1A,[9] the radial artery then passes beneath the tendons of the abductor pollicis longus and extensor pollicis longus and brevis. While the ulnar artery predominately forms the superficial palmar arch, the deep palmar arch arises from the terminal part of the radial artery and anastomoses with the ulnar artery distally. An important branch of the radial artery is the recurrent radial artery, which arises from the radial artery below the elbow and passes between the brachioradialis and brachialis muscles while supplying those muscles and finally anastomoses with the terminal part of the deep brachial artery (Fig. 1B).[10] Cannulation of the recurrent radial artery has been associated with complications including perforation during TRI. Knowledge of this anatomy sheds light on why challenges are encountered more often with radial access as compared to femoral access. The radial artery negotiates muscles and tendons of the forearm and arm and is predisposed to a higher incidence of loops and turns. Due to the embryological development of the radial artery from a capillary plexus from the dorsal aorta, there is

*Abbreviations:* TRI, Transradial Intervention; STEMI, ST Elevation Myocardial Infarction; BAT, Balloon Assisted Tracking; JL, Judkins Left; JR, Judkins Right; EBU, Extra Back Up.

* Corresponding author. 755 E McDowell Rd, Floor 4, Phoenix, AZ, 85006, USA.
*E-mail address:* ashish.pershad@bannerhealth.com (A. Pershad).

https://doi.org/10.1016/j.ihj.2020.09.012
0019-4832/© 2020 Published by Elsevier B.V. on behalf of Cardiological Society of India. This is an open access article under the CC BY-NC-ND license (http://creativecommons.org/licenses/by-nc-nd/4.0/).

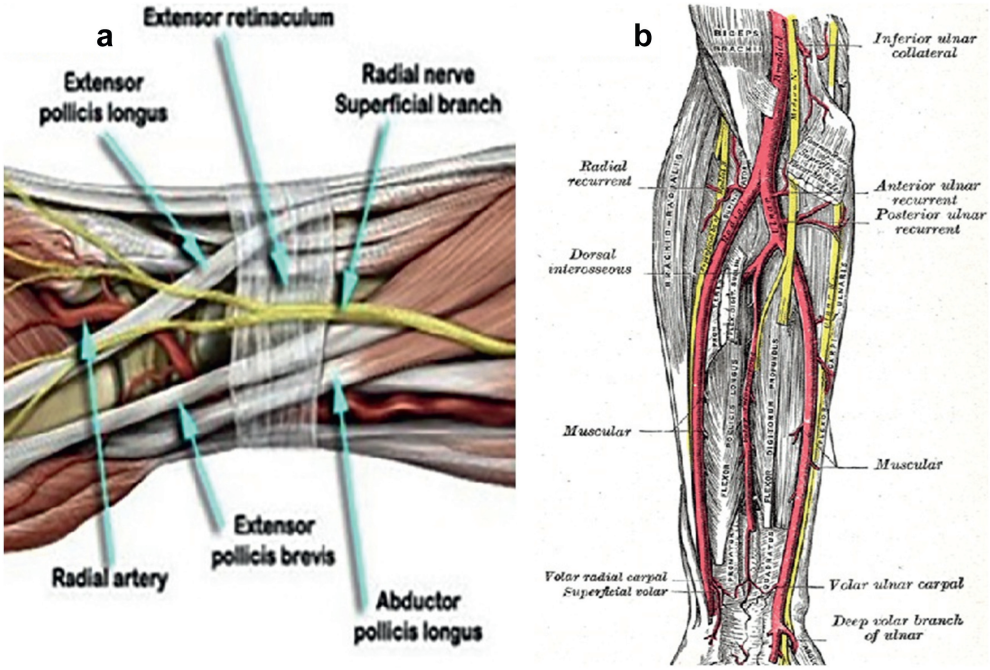


**Fig. 1.** a and b-Clinical Anatomy of the Radial Artery (With permission from Wiley. Catheter Cardiovasc Interv. 2019 Mar 1; 93 (4):639–644).

substantial inter-patient variability in the anatomy, which poses challenges during access.[11]

## 3. Access challenges

### 3.1. Algorithm for radial artery spasm

When it comes to radial artery spasm, the saying "an ounce of prevention is worth a pound of cure" could not be more apropos. Ways to prevent radial artery spasm are:

(a) Adequately relaxing and sedating the patient prior to attempt at access.[12] (b) Minimizing attempts, especially if the vessel is small in caliber or difficult to palpate. Point of care ultrasound and counter-puncture technique by transfixing the radial artery have been shown to be useful to minimize attempts at access.[13,14] If spasm occurs prior to obtaining access, waiting for the spasm to abate and subcutaneous administration of nitroglycerin at near the access site are potential solutions[15] (c) Smallest caliber sheaths with hydrophilic coating and a tapered tip lower the occurrence of spasm. The incidence of spasm is not impacted by sheath length.[16] (d) Radial cocktail of Verapamil and Nitroglycerin has been shown to be most effective as a spasmolytic.[17] In patients with anticipated spasm nitroglycerine can be mixed with local anesthesia for local infiltration before puncture can be attempted.

Spasm in its extreme form especially after a long procedure with multiple catheter exchanges in a female patient can cause device entrapment (either sheath or in rare instances even the guiding catheter). The algorithm is the same as described in the preceding paragraph with escalation to the following steps-

(a). Ischemia and hyperemia mediated vasodilatation. In this technique, a blood pressure cuff is inflated to above systemic pressure for 5 min. This induces ischemia of the forearm and hand. On release of the cuff, hyperemia and vasodilatation ensue, and can relive spasm.[18]
(b). Propofol administration for "deep sedation". This often involves calling in the services of an anesthesiologist.
(c). General anesthesia with administration of paralytic agents.
(d). In extreme cases, femoral access followed by selective cannulation of the innominate/subclavian artery and angiography is necessary to identify the extent of the spasm. This often reveals, passage of equipment through an aberrant vessel in the forearm. Angioplasty over an 0.014 wire and coronary balloon can be performed next to the entrapped gear to relieve recalcitrant spasm (Video1a-e).

A detailed algorithm dealing with spasm before, during and after the procedure is outlined in Fig. 2.

### 3.2. Algorithm for tortuosity in the arm

Tortuosity is encountered in 2.7% of TRI cases.[19] Without a well-defined algorithm, improper management of tortuosity can lead to procedural failure or worse a procedural complication like a perforation.

The first step when resistance is encountered in the passage of a wire is to define the problem with an angiogram using diluted contrast either through the side port of the sheath if resistance is in the forearm or through the catheter if the resistance is higher up.

If a loop is noted, then downsizing the wire to an 0.025″, 0.018″ or 0.014″ wire is the first next step. The catheter is then advanced over the lower profile wire. If unable to advance the catheter over the lower profile wire, a maneuver called "straightening the loop" is performed. This involves advancing the lower profile wire as far beyond the loop as possible and the catheter as far into the loop as possible. Pulling the entire assembly back with slight rotation opens the loop and straightens the segment. Sometimes, a coiled convex tip of a 1 Fr smaller pigtail catheter exiting the guide can serve as a bumper and allow for tracking the catheter over the wire. Balloon assisted tracking (BAT), by using a partially inflated balloon protruding out from the catheter allows for negotiation of tortuosity when the simpler methods described earlier fail. A 0.035″ compatible balloon or 0.014″compatible balloon can be used[20] (Video 2). The detailed algorithm is outlined in Fig. 3.

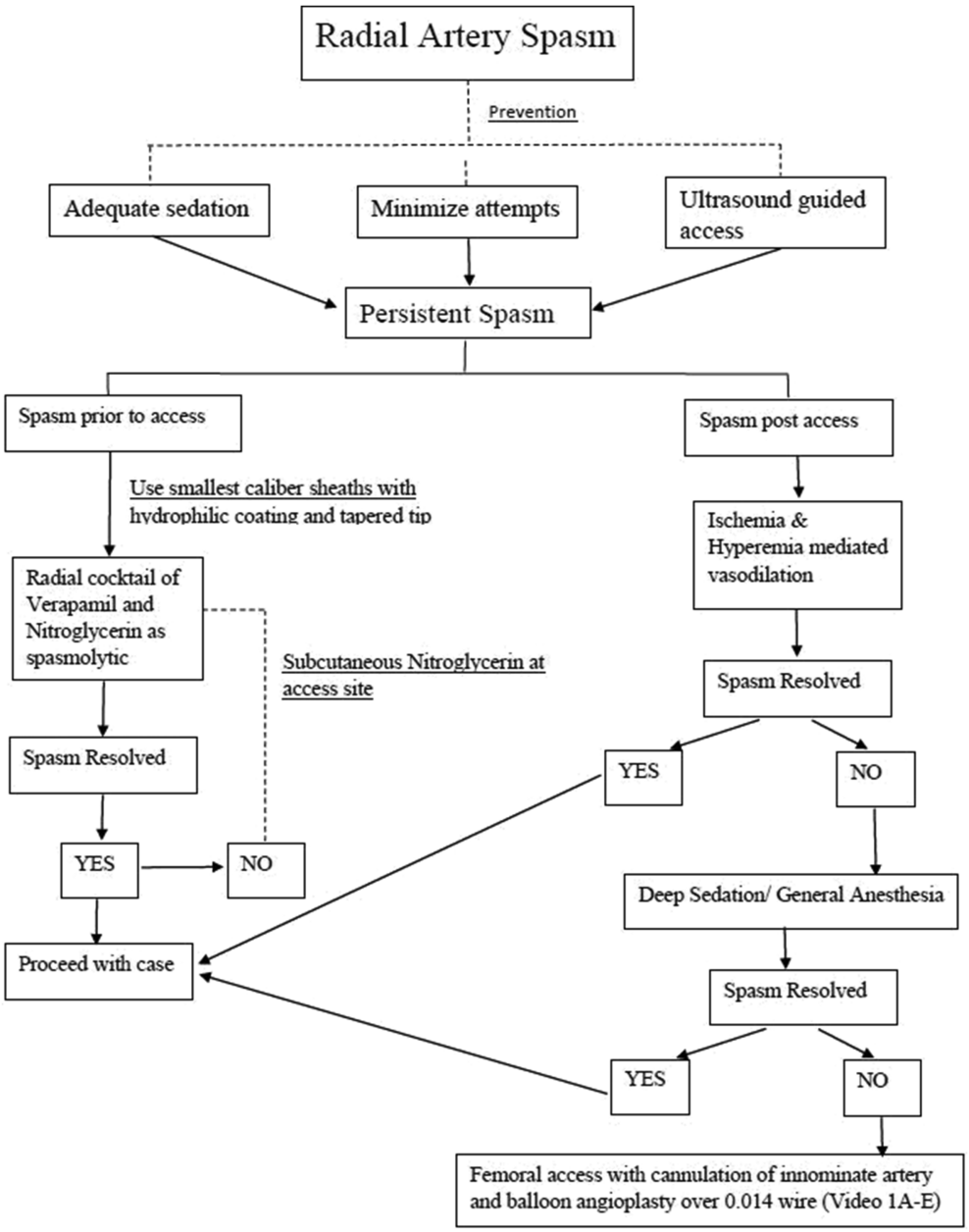


**Fig. 2.** Algorithm for spasm during Transradial Interventions (TRI).

### *3.3. Algorithm for tortuosity in the subclavian, innominate and aortic arch*

Negotiation of the obtuse angle of the innominate aortic junction is unique to TRI. Due to the risk of injury to large bore vessels in the thorax, careful procedural consideration is necessary. The simplest way to negotiate a simple loop or tortuosity is have the patent take a deep breath while advancing the wire under fluoroscopic visualization. The caudal displacement of the diaphragm and the intrathoracic vessels with inspiration eases the passage of gear through the innominate and subclavian vessels. Use of BAT, like that described for tortuosity in the forearm is the safest next step. The use of stiff hydrophilic coated 0.038″ wires like the Glidewire Advantage (Terumo, Somerset NJ) has been recommended to negotiate subclavian and innominate tortuosity.[21] The authors believe that extreme tortuosity in the innominate/subclavian and stiff hydrophilic wires is a dangerous liaison. Due to the lack of tactile feedback from the tip of the hydrophilic wire, it is not uncommon to get under a dissection flap with extension of this into the aorta (Video 3a,3b). As opposed to hydrophilic wires, it is safe to advance a hydrophobic floppy wire such as the Wholey (Covidien, Mansfield MA) with its tip prolapsed. Unlike 0.035- inch hydrophilic wires, the Wholey (Covidien, Mansfield MA) floppy wire has excellent steerability. There is also much better tactile feel and control of this family of wires when negotiating tortuous vessels. Hydrophilic wires tend to jump uncontrollably through difficult anatomy, and the risk of dissection is real. The TAD wire (Covidien, Mansfield MA) has a tapered 0.018-inch tip that transitions to a 0.035-inch body and may be useful for crossing very tight lesions. After using a hydrophobic 0.035″ wire and after techniques like BAT over 0.014″ or 0.018″ wires, if tortuosity cannot be traversed, serious consideration must be given to switch to either the

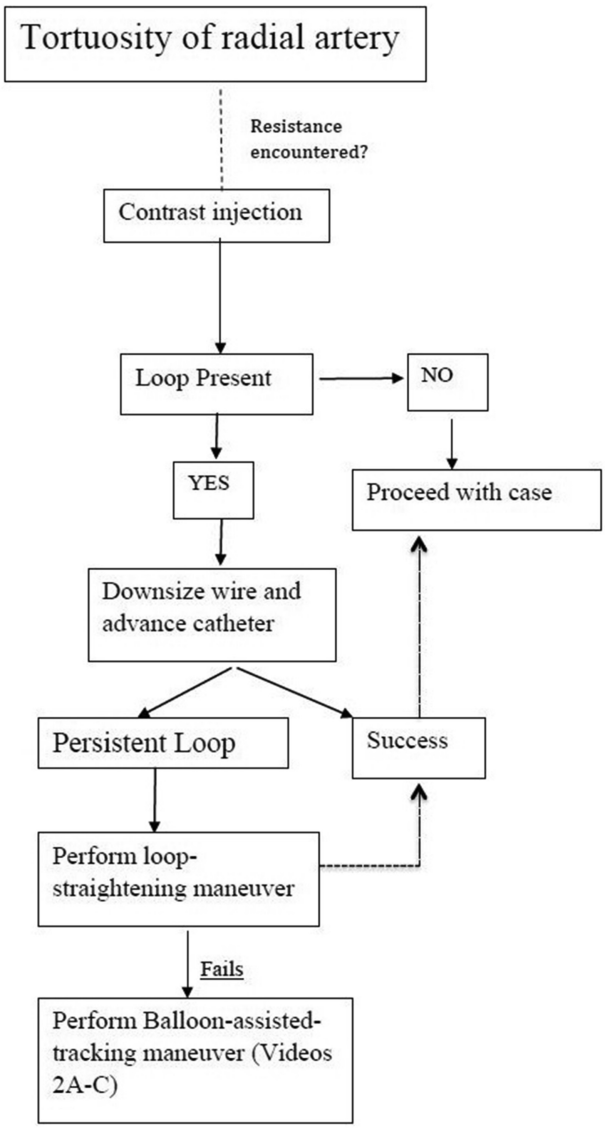


**Fig. 3.** Algorithm for tortuosity during Transradial Interventions (TRI).

contralateral radial or even a cross over to the femoral approach. The detailed algorithm is outlined in Fig. 4.

### 3.4. Algorithm for guiding catheter choice for TRI

Inadequate guiding catheter support from the radial access accounts for 17% percent of failures of TRI.[22] In most instances, guiding catheters used from the femoral approach can be used for TRI. Left sided catheters are typically downsized by ½ cm. e.g. A JL3.5 instead of a JL 4 or an EBU 3.0 instead of an EBU 3.5. Alternatives are needed when the root size is small especially in combination with an obtuse innominate-aortic angle. In such scenarios, the opposite aortic wall can be used as a fulcrum, for helping with guide engagement and support. Amplatz left sided curves are the next choice of guide catheter followed by dedicated radial catheters like the Ikari left 3.5 cm (Fig. 5a and b). For the right coronary artery (RCA) Judkins right is still the most common catheter used for RCA and provides good support for most procedures. For patients requiring extra support, XB-RCA, Amplatz Right and Multipurpose curves are the preferred shapes that the authors recommend. Amplatz and Ikari (Terumo, Somerset, NJ) curves increase the risk of dissection of coronary ostia because of non-coaxial engagement sometimes made worse with respiratory variation especially when used with automated injectors. Catheters can additionally be selected based on angiography assessment considering the origin and lesion complexity.

### 3.5. Algorithms for catheter kinks and knots

Prevention is the best strategy to prevent knotting/kinking of catheters. Over-rotating a catheter greater than $180^0$ in the same direction will prevent the transmission of torque from the proximal end to the distal end of the catheter causing it to torque or kink. The first sign of a catheter kink is the loss or dampening of the arterial pressure tracing. Leaving a 0.035″ wire inside the catheter while manipulation of the catheter is performed, prevents it from kinking. If the catheter is a guiding catheter and connected to a Y adaptor simultaneous injection of contrast is feasible.[23] Catheter kinking should thus be suspected in the absence of torque transmission and inability of contrast injection in addition to loss of pressure tracing. The algorithm for managing a kink or twist is:

(a) Untwisting of the catheter knot by rotation in the opposite direction. This maneuver is facilitated by keeping a 0.035″ hydrophilic stiff wire within the catheter that can be used to cross the kink.
(b) External Fixation of the catheter at the level of the arm by inflation of a sphygmomanometer. This external fixation allows more effective untwisting.
(c) Using a larger sheath - This technique involves cutting the hub of the knotted catheter and removing the sheath that was used for the procedure. Replacing the sheath with a larger and longer sheath and advancing it to the kinked segment of the catheter allows gently retracting the catheter into the larger sheath and its withdrawal.[24]
(d) Internal Fixation with femoral access and advancement of a 6Fr catheter into the innominate and snaring the proximal end of the kinked catheter fixates the catheter for untwisting at the wrist with gentle advancement of a 0.035″ hydrophilic wire through the catheter.[25] The detailed algorithm for managing a catheter kink is outlined in Fig. 6.

### 3.6. Algorithms for radial artery perforation

Radial artery perforation is a dreaded complication that can occur during TRI, especially when patient is on therapeutic anticoagulation during percutaneous coronary intervention. Prompt identification and management of radial artery perforation is required to avoid compartment syndrome. The perforated segment should be crossed meticulously with a guidewire using balloon assisted tracking and guide catheter tamponade is the recommended strategy.[26] Additionally, external compression with a sphygmomanometer cuff at the level of systolic blood pressure located slightly above the bleeding site is recommended. Typically, protamine administration is not required. If the perforation is not sealed by these maneuvers, urgent consultation with a vascular surgeon is recommended to avoid development of compartment syndrome.

### 3.7. Direct femoral access

The authors would like to acknowledge that “radial first” approach may not be suitable for all patients. There are certain patient related conditions that may preclude radial access and a direct femoral approach is recommended to avoid re-sticking for access and reduce patient discomfort. Patient with documented

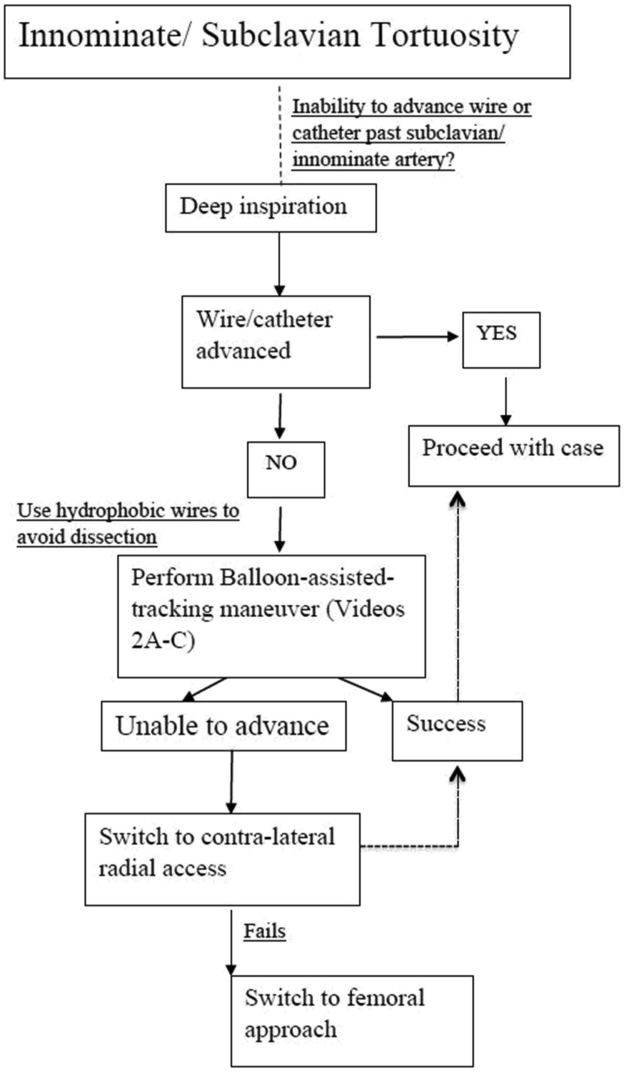


**Fig. 4.** Algorithm for innominate/subclavian tortuosity during Transradial Interventions (TRI).

history of radial artery occlusion or complications may benefit with direct femoral approach. Although, ulnar access may be considered there is risk of causing hand ischemia if the ulnar arterial supply is jeopardized due to lack of collateral circulation by the ipsilateral

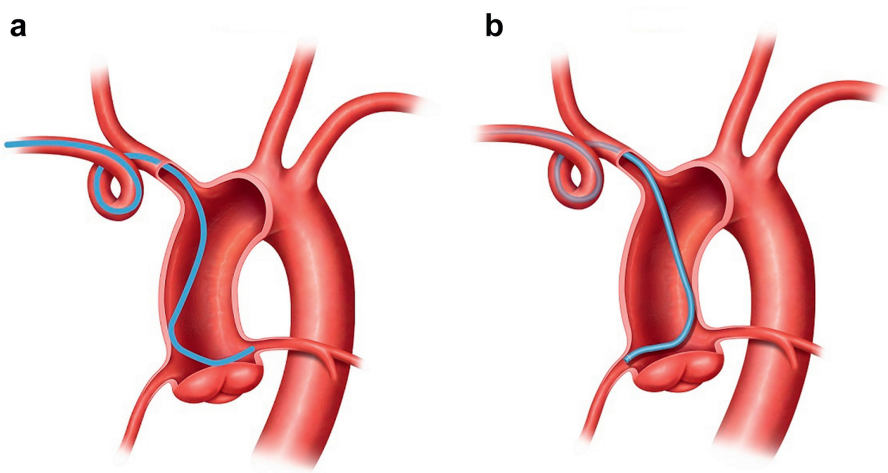


**Fig. 5.** a and b-Obtuse angulation of the innominate with a short aortic root. An Amplatz 0.75 guiding catheter engaging the RCA and an Ikari 3.5 engaging the LCA, leveraging the opposite aortic wall for guide support.

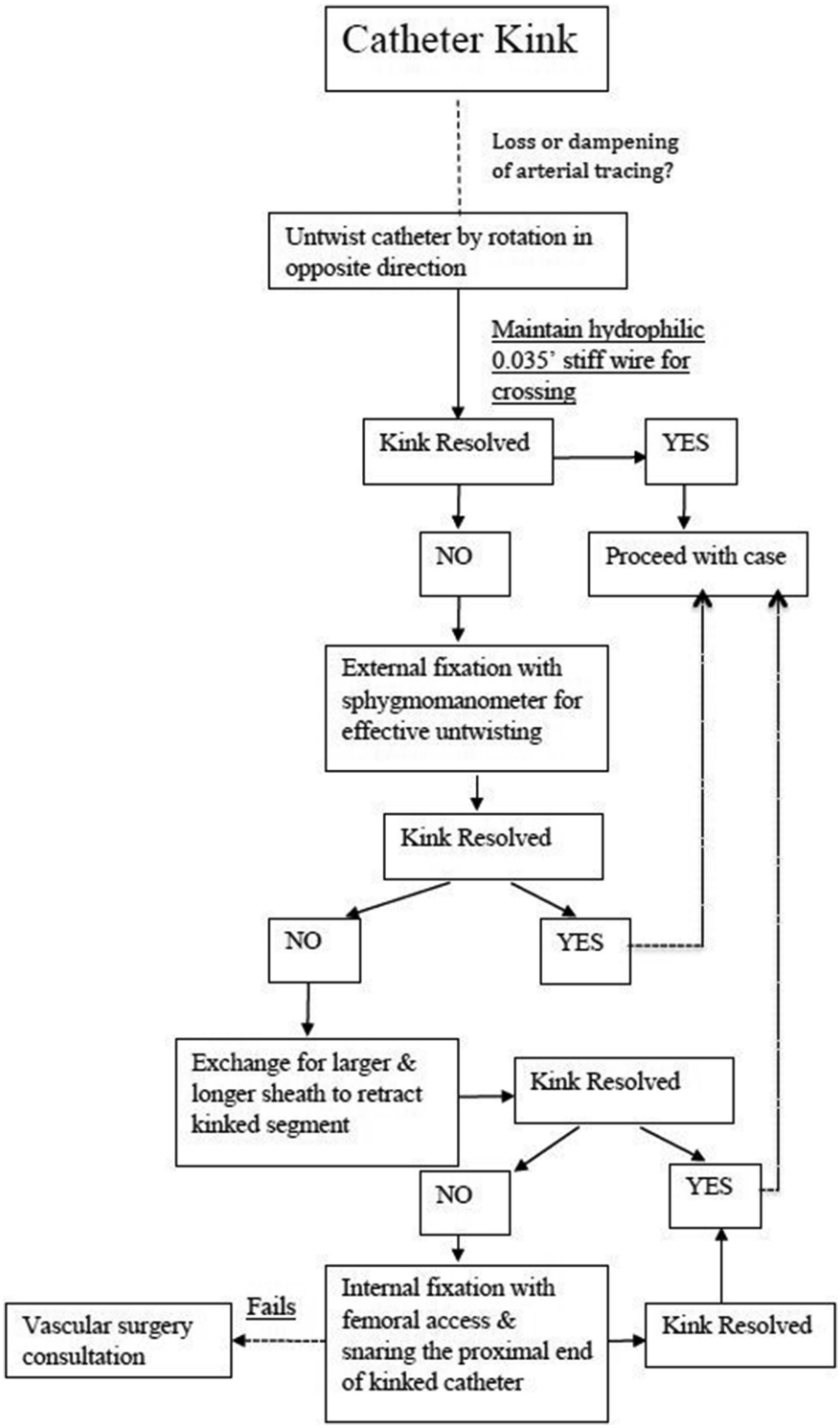


**Fig. 6.** Algorithm for catheter kink during Transradial Interventions (TRI).

occluded radial artery. Some providers may consider using the contralateral limb radial artery for access if no history of complications. The authors would like to emphasize the importance of administering anticoagulation during the procedure and using "patent hemostasis" when applying the radial TR band post-procedure for reducing risk of radial artery occlusions.

## 4. Conclusions

When an unexpected event happens with potential for harm to the patient during a procedure, an interventional cardiologist is caught off guard. With a check list or algorithm, the situation can

often be managed successfully. This paper provides radial operators algorithmic solutions to challenges encountered during TRI.

## Conflicts of interest

All authors have none to declare.

## Appendix A. Supplementary data

Supplementary data to this article can be found online at https://doi.org/10.1016/j.ihj.2020.09.012.

## References


1. Feldman DN, Swaminathan RV, Kaltenbach LA, et al. Adoption of radial access and comparison of outcomes to femoral access in percutaneous coronary intervention: an updated report from the National Cardiovascular Data Registry (2007-2012). *Circulation*. 2013;127:2295–2306.
2. Rao SV, McCoy LA, Spertus JA, et al. An updated bleeding model to predict the risk of post-procedure bleeding among patients undergoing percutaneous coronary intervention: a report using an expanded bleeding definition from the National Cardiovascular Data Registry CathPCI Registry. *JACC Cardiovasc Interv*. 2013;6:897–904.
3. Rao SV, Cohen MG, Kandzari DE, et al. The transradial approach to percutaneous coronary intervention: historical perspective, current concepts, and future directions. *J Am Coll Cardiol*. 2010;55:2187–2195.
4. Valgimigli M, Gagnor A, Calabró P, et al. Radial versus femoral access in patients with acute coronary syndromes undergoing invasive management: a randomised multicentre trial. *Lancet*. 2015;385:2465–2476.
5. Romagnoli E, Biondi-Zoccai G, Sciahbasi A, et al. Radial versus femoral randomized investigation in ST-segment elevation acute coronary syndrome: the RIFLE-STEACS (Radial versus Femoral Randomized Investigation in ST-Elevation Acute Coronary Syndrome) study. *J Am Coll Cardiol*. 2012;60:2481–2489.
6. Mehta SR, Jolly SS, Cairns J, et al. Effects of radial versus femoral artery access in patients with acute coronary syndromes with or without ST-segment elevation. *J Am Coll Cardiol*. 2012;60:2490–2499.
7. Ibanez B, James S, Agewall S, et al. 2017 ESC Guidelines for the management of acute myocardial infarction in patients presenting with ST-segment elevation: the Task Force for the management of acute myocardial infarction in patients presenting with ST-segment elevation of the European Society of Cardiology (ESC). *Eur Heart J*. 2018 Jan 7;39(2):119–177.
8. Riley RF, Walsh SJ, Kirtane AJ, et al. Algorithmic solutions to common problems encountered during chronic total occlusion angioplasty: the algorithms within the algorithm. *Cathet Cardiovasc Interv*. 2019;93(2):286–297.
9. Corcos T. Distal radial access for coronary angiography and percutaneous coronary intervention: a state-of-the-art review. *Cathet Cardiovasc Interv*. 2019 Mar 1;93(4):639–644.
10. *Gray's Anatomy: The Anatomical Basis of Clinical Practice*. 41ST ed. Philadelphia: Elsevier Limited; 2016.
11. Rodríguez-Niedenführ M, Burton GJ, Deu J, et al. Development of the arterial pattern in the upper limb of staged human embryos: normal development and anatomic variations. *J Anat*. 2001;199(Pt 4):407–417.
12. Deftereos S, Giannopoulos G, Raisakis K, et al. Moderate procedural sedation and opioid analgesia during transradial coronary interventions to prevent spasm: a prospective randomized study. *JACC Cardiovasc Interv*. 2013;6(3):267–273.
13. Seto AH, Roberts JS, Abu-Fadel MS, et al. Real-time ultrasound guidance facilitates transradial access: RAUST (Radial Artery access with Ultrasound Trial). *JACC Cardiovasc Interv*. 2015;8(2):283–291.
14. Pancholy SB, Sanghvi KA, Patel TM. Radial artery access technique evaluation trial: randomized comparison of Seldinger versus modified Seldinger technique for arterial access for transradial catheterization. *Cathet Cardiovasc Interv*. 2012;80(2):288–291.
15. Pancholy SB, Coppola J, Patel T. Subcutaneous administration of nitroglycerin to facilitate radial artery cannulation. *Cathet Cardiovasc Interv*. 2006;68(3):389–391.
16. Rathore S, Stables RH, Pauriah M, et al. Impact of length and hydrophilic coating of the introducer sheath on radial artery spasm during transradial coronary intervention: a randomized study. *JACC Cardiovasc Interv*. 2010;3(5):475–483.
17. Kwok CS, Rashid M, Fraser D, et al. Intra-arterial vasodilators to prevent radial artery spasm: a systematic review and pooled analysis of clinical studies. *Cardiovasc Revascularization Med*. 2015;16(8):484–490.
18. Pancholy SB, Karuparthi PR, Gulati R. A novel nonpharmacologic technique to remove entrapped radial sheath. *Cathet Cardiovasc Interv*. 2015;85(1):E35–E38.
19. Barbeau GR. Radial loop and extreme vessel tortuosity in the transradial approach: advantage of hydrophilic-coated guidewires and catheters. *Cathet Cardiovasc Interv*. 2003;59(4):442–450.
20. Patel T, Shah S, Pancholy S, et al. Balloon-assisted tracking: a must-know technique to overcome difficult anatomy during transradial approach. *Cathet Cardiovasc Interv*. 2014;83(2):211–220.
21. Patel T, Shah S, Pancholy S, et al. Working through challenges of subclavian, innominate, and aortic arch regions during transradial approach. *Cathet Cardiovasc Interv*. 2014;84(2):224–235.
22. Dehghani P, Mohammad A, Bajaj R, et al. Mechanism and predictors of failed transradial approach for percutaneous coronary interventions. *JACC Cardiovasc Interv*. 2009;2(11):1057–1064.
23. Ben-Dor I, Rogers T, Satler LF, et al. Reduction of catheter kinks and knots via radial approach. *Cathet Cardiovasc Interv*. 2018;92(6):1141–1146.
24. Aminian A, Fraser DG, Dolatabadi D. Severe catheter kinking and entrapment during transradial coronary angiography: percutaneous retrieval using a sheathless guide catheter. *Cathet Cardiovasc Interv*. 2015;85(1):91–94.
25. Khoubyari R, Arsanjani R, Habibzadeh MR, et al. Successful removal of an entrapped and kinked catheter during right transradial cardiac catheterization by snaring and unwinding the catheter via femoral access. *Cardiovasc Revascularization Med*. 2012;13(3):202.e1–202.e3.
26. George S, Mamas M, Nolan J, Ratib K. Radial artery perforation treated with balloon tracking and guide catheter tamponade - a case series. *Cardiovasc Revascularization Med*. 2016;17(7):480–486.