Indian Heart Journal 73 (2021) 325–330

Contents lists available at ScienceDirect

Indian Heart Journal

journal homepage: www.elsevier.com/locate/ihj

Original Article

The relation between QRS complex fragmentation and segmental abnormalities of the myocardial contractility in patients with coronary artery disease

Judith María Torales [a, b, 1], Osmar Antonio Centurión [a, b, *, 1], Nelson J. Aquino [a], Christian O. Chávez [a], José F. Alderete [a, b], Karina E. Scavenius [a, b], Orlando R. Sequeira [a], Luis M. Miño [a, b], José C. Candia [a], Cristina Cáceres [a], Oscar A. Lovera [a], Jorge E. Martínez [a]

[a] Department of Cardiology, Hospital de Clínicas, Asunción National University (UNA), San Lorenzo, Paraguay
[b] Department of Health Sciences Investigation, Sanatorio Metropolitano, Fernando de La Mora, Paraguay

ARTICLE INFO

Article history:
Received 30 May 2020
Received in revised form
15 February 2021
Accepted 23 March 2021
Available online 29 March 2021

Keywords:
Fragmented QRS complex
Myocardial contractility
Coronary artery disease
Hypokinesia

ABSTRACT

Background: Fragmented QRS (fQRS) is defined as any QRS complex with duration of less than 120 ms (ms) and at least one notch in the R or S wave in two or more leads belonging to the same coronary territory. The fQRS represents a delay in ventricular conduction caused by a myocardial scar associated to arrhythmic events.
Methods: This is a descriptive, retrospective, cross-sectional study of a total of 123 patientsadmitted with ischemic heart disease. The aim was to correlate the presence of fQRS in a conventional 12-leads electrocardiogram (ECG) with myocardial regional motility disorders.
Results: A total of 62% of the patients were male, the mean age was 63 ± 12 SD. fQRS was observed in 44% (64% men and 36% women), the most frequent location being the inferior wall (61%), followed by the anteroseptal and lateral walls (14% for both). Of the 36 patients with fQRS, 30 had segmental disorders, while 6 did not. Of the 45 patients without fQRS, 28 had segmental disorders, but 17 did not, which gives us a sensitivity of 52% (moderate SnNout) and specificity of 74% (high SpPin), with a positive predictive value of 83%, a negative predictive value of 38% and a prevalence of 72%.
Conclusion: The presence of fQRS in the ECG has high specificity and a high positive predictive value of the existence of segmental myocardial motility disorders in patients with documented coronary artery disease.
© 2021 Cardiological Society of India. Published by Elsevier B.V. This is an open access article under the CC BY-NC-ND license (http://creativecommons.org/licenses/by-nc-nd/4.0/).

1. Introduction

Cardiovascular diseases are the leading cause of illness and death in developed countries and it is expected that for the next decade it will also be in developing countries.[1–3] Coronary artery disease (CAD) stands out for being the most prevalent and presenting high morbidity and mortality.[4–6] The predictors of poor prognosis in CAD are decreased left ventricular function, ventricular remodeling, and the development of potentially malignant arrhythmias.[7–11] In recent years the search for new predictors of poor prognosis in CAD has revealed the presence of fragmented QRS (fQRS).[11–21]

The fQRS, evaluated on the 12-lead electrocardiogram (ECG), represents a delay in ventricular conduction caused by the presence of a myocardial scar. Even without being specific to CAD, it was associated to an increased risk of mortality and arrhythmic events as an addition to the already known ejection fraction (EF), which proved to be a good prognostic marker.[16–24] The fQRS was defined as a QRS complex with duration of less than 120 ms and at least one notch in the R or S wave in two or more leads belonging to the same coronary territory.[21–26] fQRS is a simple marker of non-invasive electrocardiographic depolarization used to identify individuals at high risk of ventricular arrhythmias and sudden cardiac death in various clinical settings, including CAD.[25–29]

* Corresponding author. Faculty of Medical Sciences, Asunción National University (UNA), Chief, Department of Cardiology. Hospital de Clínicas, Address: Av. Mariscal López e/ Coronel Cazal, San Lorenzo, Paraguay.
E-mail address: osmarcenturion@hotmail.com (O.A. Centurión).
[1] Judith M. Torales and Osmar A. Centurión contributed equally to this work.

https://doi.org/10.1016/j.ihj.2021.03.010
0019-4832/© 2021 Cardiological Society of India. Published by Elsevier B.V. This is an open access article under the CC BY-NC-ND license (http://creativecommons.org/licenses/by-nc-nd/4.0/).

It has been demonstrated that fQRSis a useful indicator as a diagnostic tool for the detection of myocardial infarction, and also as a predictor of cardiac events including progression of heart failure and death after acute coronary syndrome.[25–29] Moreover, fQRS has beenshown to be a sign of myocardial scar tissue formation based on myocardialperfusion studies.[30] However, the sensitivity, specificity and predictive value of fQRS for predicting alteration in myocardial contractility in patients with documented chronic CAD remains scantly known. Therefore, we aim to analyze and correlate the presence of fQRS with myocardial regional motility disorders in patients with chronic CAD. We also sought to determine the prevalence of the presence of fQRS in the electrocardiograms of our study patients to identify the most frequent electrocardiographic location of QRS fragmentation, and to determine the type of motility disorder in these patients and their location. To the best of our knowledge this the first study to evaluate the sensitivity, specificity and predictive values of the fQRS in predicting echocardiographic alterations of the myocardial contractility in coronary angiography proven CAD.

2. Materials and methods

2.1. Study patients

In a descriptive, retrospective, cross-sectional study, a total of 123 patients were admitted to the Cardiology Department of the Hospital de Clínicas with chronic CAD during the period from March 2016 to February 2017 and studied with noninvasive diagnostic methods and coronary angiography. Although, most of the patients had documented signs of CAD with non-invasive studies, 81 non-consecutive patients had their CAD corroborated by coronary angiography. CAD was defined as the presence of a stenoticatheromatous plaque producing a greater than 50% stenosis on coronaryangiography. The studies were conducted in accordance with the ethical standards of the 1964 Helsinki Declaration and its later amendments or comparable ethical standards with the approval of the localinstitutional ethics review board.

2.2. Study variables and statistics

The 12 leads conventional ECG were taken with an electrocardiographer MAC 600 GE Medical Systems Information Technologies, Inc, Milwake, WI, USA, at a speed of 25 mm/s, with automatic standardizations according to voltage. The measurements were made manually, avoiding automated measurements. Regarding the FQRS, the patients who presented it were grouped according to the affected walls in inferior, antero-septal, anterior, lateral, and the combination of any of these. The existence of FQRS on 12-lead ECG was defined according to previous related investigations.[17–19] An example of FQRS is shown in Fig. 1. In patients with narrow QRS, namely, QRS less than 120 ms, the definition of FQRS comprised the presence of an additional R wave (R′) or notching in the nadir of the R wave or the S wave, or the presence of one R' (fragmentation) in two contiguous leads. In patients with wide QRS, FQRS was defined as two notches in the R or S wave in two contiguous leads.

We analyzed: age, sex, cardiovascular risk factors, symptoms, NYHA functional class, the presence and location of fQRS on the electrocardiogram, the ejection fraction (EF) and regional myocardial motility disorders with their respective location on the echocardiography.[30] The variables were recorded in the Excel 2007 spreadsheets. The analysis was performed using EPI Info statistical version 7.2.0.1 and Epidat 3.1 software's. In the descriptive analysis, the qualitative variables were expressed in frequencies and percentages, and the quantitative variables in means and standard deviations (SD); or as medians and interquartile ranges. In the qualitative variables, the sensitivity and specificity were analyzed with 95% confidence intervals. The electrocardiograms and echocardiographies were reviewed independently by two researchers (JT and NA), and the measurements were entered in duplicate to eliminate interobserver variability. Kappa values were utilised to determine interobservervariability and reliability for categorical variables; values of 0.81–1.0 are indicative of excellent agreement; 0.61–0.80, substantial agreement; 0.41–0.60, moderate agreement; 0.21–0.40, fair agreement; 0–0.20, slight agreement; and values ≤ 0, poor agreement.[31] This method produced an excellent correlation between the two observations with a kappa statistic of 0.92. If there was discrepancy between the two recordings, the original electrocardiogram was retrieved and reassessed by the two researchers and reviewed with a third cardiologist (OC), together until a consensus was reached. We estimated the strength of the associations using 95% confidence intervals and a p-value < 0.05 was considered statistically significant.

3. Results

Of the total 123 patients with ischemic heart disease, 81 had documented coronary artery disease by coronary angiography. These are the patients entered for further analysis. Of all the patients 62% were male and 38% were female, the average age was 63 ± 12 SD, the minimum age being 36 years and the maximum age 94 years. Most of the patients(78%) had high blood pressure, 25% had type 2 diabetes mellitus, 25% had dyslipidemia, 12% obesity, 11% family history and 33% smoking.

There were 47% of the patients admitted due to dyspnea and 53% due to chest pain not related to acute coronary syndrome.Of de total number of patients with documented CAD, 44, 4% presented fQRS (64% men and 36% women), the most frequent location being the inferior wall, followed by the anteroseptal and lateral walls, then the inferolateral involvement, and in a smaller percentage the rest of the walls as depicted in Fig. 2. The mean ejection fraction (EF) was $48 \pm 13\%$. Alterations in myocardial contractility were found in 80% of the patients (akinesia, hypokinesia or dyskinesia). The most frequent locations showing no significant difference were in the apical (52%), inferior (49%), and septal walls (47%). Most of the patients with fQRS, especially in the inferior leads, had also small Q waves, as the ones that can be seen in the inferior leads ofour Fig. 1. Therefore, fQRS did not provide incremental value over abnormal Q waves in predicting wall motion abnormalities.

Of the 36 patients with fQRS, 30 had segmental disorders, while 6 patients did not. Of the 45 patients without fQRS, 28 had segmental disorders, while 17 patients did not, which gives us a sensitivity of 52% (moderate SnNout), and a specificity of 74% (high SpPin) in the prediction of alterations in myocardial contractility. The positive predictive value was 83%, and the negative predictive value was 38% (Table 1). The prevalence value was found to be 72%. Fig. 3 depicts the receiver operating characterisitic (ROC) curve ofthe QRS complex fragmentation for abnormalities of the myocardial contractility.

4. Discussion

To the best of our knowledge this the first study to evaluate the sensitivity, specificity and predictive values of the fQRS in predicting alterations of the myocardial contractility in coronary angiography proven CAD. In the present work we have demonstrated that the presence of QRS complex fragmentation in the electrocardiogram has a high specificity and a high positive predictive value of the existence of segmental disorders of myocardial

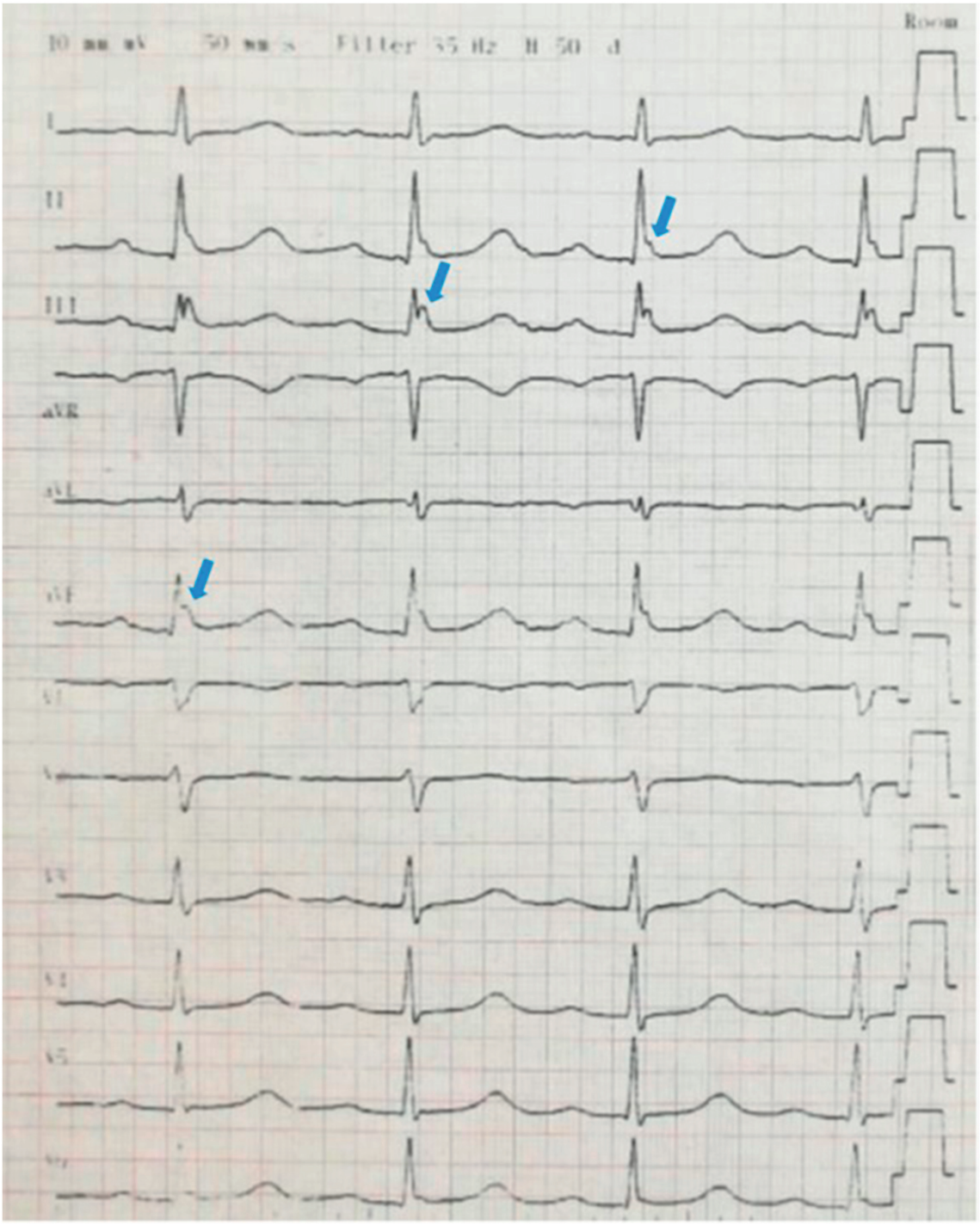

Fig. 1. A conventional, standard 12 leads electrocardiogram showing fragmented QRS complexes (blue arrows) in DII, DIII, andaVF.

contractility in patients with coronary artery disease. This has inherent clinical implication since with a simple electrocardiogram that is an efficient, fast, cheap and highly available diagnostic auxiliary method; we may assume that a patient may also have segmental parietal motility abnormalities of the ventricular myocardium.

Fragmented QRS is a novel ECG parameter thatcan be assessed from aninexpensive, easily obtainable, and fast conventional procedure; a standard 12-lead ECG. Fragmented QRS complexes may represent conduction abnormalities or peri-infarction block related tomyocardial scar or necrosis.[32–34] This fQRS is defined by the finding of additional notching within the QRS complex morphology in two contiguous leads corresponding to a major coronary arteryterritory, resulting in various RSR' patterns on the resting 12-lead ECG.[32]QRS complex fragmentation represents myocardial conduction block due to myocardial scar that can be detected by myocardial single-photon emission computed tomography.[30] Therefore, fQRS may be helpful to detect myocardial scars of prior myocardial infarction, providing an organized location of the scar tissue and dysfunctional myocardium. Indeed, we have found in the present

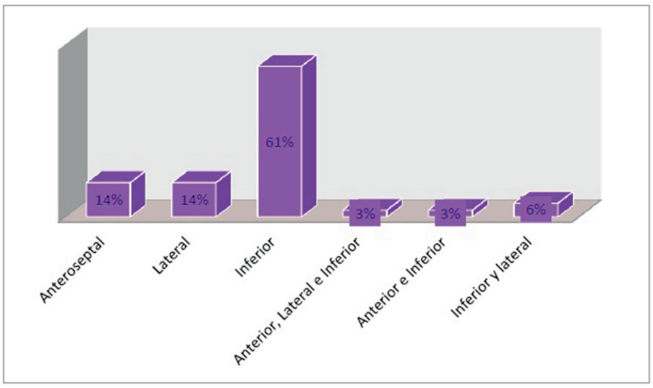

Fig. 2. More frequent locations of fragmented QRS complexes in the electrocardiogram.

study that the most frequent location of fQRS was the inferior wall, followed by the anteroseptal and lateral walls, and then the inferolateral wall involvement. However, probably due to our small population, fQRS did not provide incremental value over abnormal Q waves in predicting wall motion abnormalities. We also found that 80% of our CAD patients had alterations in myocardial contractility, namely, aquinesia, hypokinesia or dyskinesia. The most frequent locations were in the apical, inferior, and septal walls. Correlation between fQRS and wall thinning on echocardiography has not been assessed in the present study. Ciftci O et al[30] demonstrated that fQRS was significantly correlated with myocardial scar, as well as, with the presence of perfusion defects, indicating that at least some fQRS patterns may also result from ischemic but viable myocardium with slowed or blocked conduction. In this context, other studies have shown delayed or blocked conduction within ischemic but viable myocardium.[33–36] QRS complex fragmentation combined with abnormal perfusion was significantly correlated with severe CAD. Therefore, fQRS is not only indicative of myocardial scar, but may also represent ischemic myocardium evocative of severe CAD. This fact is clinically relevant since itmay enable fQRS to be used to detect patients with potentially salvageable myocardium who need to undergo revascularization.

Tangwiwat C, et al[37] aimed to investigate the association between fQRS complex and myocardial fibrosis in 144 patients with HCM. They found that 47 (33%) subjects had fQRS complex, and myocardial fibrosis was detected in 101 (70%). fQRS complex was found to be significantly associatedwith myocardial fibrosis in univariate analysis, but the significance could not be demonstratedin the multivariate analysis. This lack of statistical power may have been caused by the small size of their study population which could have rendered fQRS non significant in the multivariate analysis.

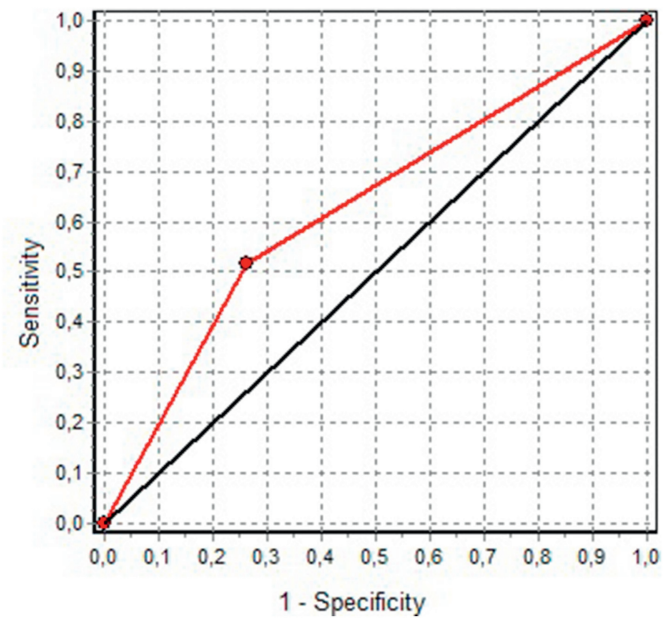

Fig. 3. Receiver operating characterisitic (ROC) curve of the QRS complex fragmentation for abnormalities of the myocardial contractility. Área ROC: 0,62 IC 95% (0,51–0,74).

Fragmented QRS complexes on routine 12-lead ECG are proposed as useful markers for identifying risk of cardiovascular events in patients with ischemic heart disease.[38–40] In a recent systematic review and meta-analysis, Kanjanahattakij N, et al[38] investigated the relation of fQRS and mortality inpatients undergoing primary percutaneous coronary intervention for ST-elevation myocardial infarction. They found an incidence of fQRS of 35% and an increased mortality compared to patients without fQRS. This incidence of fQRS is slightly lower than the one reported in our present study (44%). This is probably due to the fact that our patients had chronic CAD with higher probability for developing myocardial scars. It is interesting to note that, in the latter meta-analysis, the association remained significant after subgroup analysis of retrospective studies and even in studieswith short follow-up time. Gungor B, et al[39] conducted a previous meta-analysis in patients with myocardial infarctions and found that patients with fQRS had a higher rate of adverse events, including both long-termand short-term mortality and major adverse cardiovascular events.

A retrospective study such as ours has inherent limitations. Our study population was recruited from a single center. The size of our study population was relatively small, which means that this study may have lacked the statistical power necessary to identify all significant differences and associations. Moreover, fQRS complex

Table 1
Sensitivity and specificity of QRS complex fragmentation and its correlation with abnormalities of myocardial contractility.

		AbnormalitiesofMyocardialContractility	
		Yes	No
QRS ComplexFragmentation	Yes	30	6
	No	28	17

		ConfidenceIntervals 95%
Sensitivity	38%	(38–65)
Specificity	73%	(53–94)
Positive PredictiveValue	83%	(69–96)
Negative PredictiveValue	37%	(22–53)

and myocardial fibrosis may be caused by etiologies other than CAD, such as myocarditis, HCM and other cardiomyopathies. However, in this context, all of our patient's CAD were documented by coronary angiography, and no one had HCM.

5. Conclusion

QRS complex fragmentation is a simple, fast, and inexpensive ECG parameter that can provide valuable information for decision making in the management of patients with CAD. The presence of QRS complex fragmentation in the electrocardiogram has a high specificity and a high positive predictive value of the existence of segmental disorders of myocardial contractility in patients with coronary artery disease. This has inherent clinical implication since we may assume that a patient who presents with fQRS may also have segmental parietal motility abnormalities of the ventricular myocardium.

Funding

We received no funding, no financial support for this article.

Compliance with ethical standards

Disclosure of interest

The authors report no conflicts of interest related to this article.

Declaration of competing interest

Nothing to declare.

Acknowledgments

We thank Dr. Angelica Helga Neumann for her constant support in the making of this manuscript, and Miss Felicita Torales for her help with the literature search.

References

1. Brown RA, Shantsila E, Varma C, Lip GY. Epidemiology and pathogenesis of diffuse obstructive coronary artery disease: the role of arterial stiffness, shear stress, monocyte subsets and circulating microparticles. *Ann Med*. 2016;48(6): 444–455.
2. Lloyd-Jones D, Adams RJ, Brown TM, et al. Executive summary: heart disease and stroke statistics–2010 update: a report from the American Heart Association. *Circulation*. 2010;121:948–954.
3. Lima RS, Watson DD, Goode AR, et al. Incremental value ofcombined perfusion and function over perfusion alone by gated SPECT myocardial perfusion imaging for detection of severe three-vessel coronary artery disease. *J Am Coll Cardiol*. 2003;42(1):64–70.
4. Rhee J, Sabatine M, Llily L. Acute coronary syndromes. In: Lili L, ed. *Pathophysiology of Heart Disease: A Collaborative Project of Medical Student and Faculty*. 5th ed. Philadelphia: Lippincot Williams & Wilkins; 2011:161–189.
5. Seghieri C, Mimmi S, Lenzi J, Fantini MP. 30-dayin-hospitalmortalityafteracutemyocardialinfarction in Tuscany (Italy): anobservationalstudyusing hospital discharge data. *BMC Med Res Methodol*. 2012;12(1):170.
6. Lerner DJ, Kannel WB. Patterns of coronary heart disease morbidity and mortality in the sexes: a 26-year follow-up of the Framingham population. *Am Heart J*. 1986;111:383–390.
7. Malakar AK, Choudhury D, Halder B, Paul P, Uddin A, Chakraborty S. A review on coronary artery disease, its risk factors, and therapeutics. *J Cell Physiol*. 2019;234(10):16812–16823.
8. Taylor GJ, Humphries JO, Mellits ED, et al. Predictors of clinical course, coronary anatomy and left ventricular function after recovery from acute myocardial infarction. *Circulation*. 1980;62:960–970.
9. Weintraub WS, Taggart DP, Mancini GBJ, Brown DL, Boden WE. HistoricalMilestones in the management of stable coronary artery disease over the last half century. *Am J Med*. 2018;131(11):1285–1292.
10. Adabag AS, Therneau TM, Gersh BJ, et al. Sudden death after myocardial infarction. *J Am Med Assoc*. 2008;300:2022–2029.
11. Moss AJ, Hall WJ, Cannom DS, et al. Improved survival with an implanted defibrillator in patients with coronary disease at high risk for ventricular arrhythmia. Multicenter Automatic Defibrillator Implantation Trial Investigators. *N Engl J Med*. 1996;335:1933–1940.
12. Moss AJ, Zareba W, Hall WJ, et al. For the Multicenter Automatic Defibrillator Implantation Trial II Investigators. Prophylactic implantation of a defibrillator in patients with myocardial infarction and reduced ejection fraction. *N Engl J Med*. 2002;346:877–883.
13. Buxton AE, Lee KL, Fisher JD, et al. A randomized study of the prevention of sudden death in patients with coronary artery disease. Multicenter Unsustained Tachycardia Trial Investigators. *N Engl J Med*. 1999;341:1882–1890.
14. Moss AJ, Zareba W, Hall WJ, et al. Prophylactic implantation of a defibrillator in patients with myocardial infarction and reduced ejection fraction. *N Engl J Med*. 2002;346:877–883.
15. Buxton AE. Risk stratification for sudden death in patients with coronary artery disease. *Heart Rhythm*. 2009;6:836–847.
16. Akbarzadeh F, Pourafkari L, Ghaffari S, Hashemi M, Sadeghi-Bazargani H. Predictive value of the fragmented QRS complex in 6 month mortality and morbidity following acute coronary syndrome. *Int J Gen Med*. 2013 May 28;6: 399–404. https://doi.org/10.2147/IJGM.S40050. Print 2013.
17. Das MK, Zipes DP. Fragmented QRS: a predictor of mortality and sudden cardiac death. *Heart Rhythm*. 2009;6(3):S8–S14.
18. Das MK, Saha C, El Masry H, et al. Fragmented QRS on a 12-lead ECG: a predictor of mortality and cardiac events in patients with coronary artery disease. *Heart Rhythm*. 2007;4(11):1385–1392.
19. Das MK, Michael MA, Suradi H, et al. Usefulness of fragmented QRS on a 12-lead electrocardiogram in acute coronary syndrome for predicting mortality. *Am J Cardiol*. 2009;104(12):1631–1637.
20. Pietrasik G, Goldenberg I, Zdzienicka J, Moss AJ, Zareba W. Prognostic significance of fragmented QRS complex for predicting the risk of recurrent cardiac events in patients with Q-wave myocardial infarction. *Am J Cardiol*. 2007;100(4):583–586.
21. Kalra V, Konakondla P, Clary JM, Das MK. Fragmented QRS predicts mortality in patients with systolic heart failure. *J Am Coll Cardiol*. 2010;55(10s1). A1.E8-A1.
22. Baranchuk A, Miranda R, Femenia F. Chagas' cardiomyopathy and fragmented QRS. *Int J Cardiol*. 2012;160(2):151–152.
23. Baranchuk A, Femenia F, Lopez-Diez JC, et al. On behalf of the FECHA study investigators. Fragmented surface ECG was a poor predictor of appropriate therapies inPatients with chagas' cardiomyopathy and ICD implantation (fragmented ECG in CHAgas' cardiomyopathy study). *Ann Non inv Electrocardiol*. 2014;19(1):43–49.
24. Das MK, Khan B, Jacob S, Kumar A, Mahenthiran J. Significance of a fragmented QRS complex versus a Q wave in patients with coronary artery disease. *Circulation*. 2006;113:2495–2501.
25. Centurión OA, Aquino-Martinez NJ, Torales-Salinas JM, et al. Role of QRS complex fragmentation in patients at high risk of cardiovascular events. *M J Cardiol*. 2017;1(1), 009.
26. Qaddoura A, Digby GC, Kabali C, et al. Use of fragmented QRS in prognosticating clinical deterioration and mortality in pulmonary embolism: a meta-analysis. *Ann Noninvasive Electrocardiol*. 2018;23, e12552. https://doi.org/10.1111/anec.12552.
27. Das MK, Michael MA, Suradi H. Fragmented QRS complex on 12-lead ECG developed during the first 48 hours after acute myocardial infarction predicts mortality. *Circulation*. 2008;118:1059. S.
28. Meng L, Letsas KP, Baranchuk A, et al. Meta-analysis of fragmented QRS as an electrocardiographic predictor for arrhythmic events in patients with brugada syndrome. *Front Physiol*. 2017;8:678. https://doi.org/10.3389/fphys.2017.00678.
29. Das MK, Maskoun W, Shen C, et al. Fragmented QRS on twelve-lead electrocardiogram predicts arrhythmic events in patients with ischemic and nonischemic cardiomyopathy. *Heart Rhythm*. 2010;7(1):74–80.
30. Ciftci O, Keskin S, Karacaglar E, et al. Fragmented QRS on 12-lead electrocardiogram IsCorrelated with severe coronary artery disease andAbnormal myocardial perfusion scintigraphy results inRenal transplant candidates. Experim Clin Transpl2018;6:690-695.
31. Landis JR, Koch GG. The measurement of observer agreement for categorical data. *Biometrics*. 1977;33:159–174.
32. Lorgis L, Cochet A, Chevallier O, et al. Relationship between fragmented QRS and no-reflow, infarct size, and peri-infarct zone assessed using cardiac magnetic resonance in patients with myocardial infarction. *Can J Cardiol*. 2014;30(2):204–210.
33. Korhonen P, Husa T, et al. Fragmented QRS in prediction of cardiac deaths and heart failure hospitalizations after myocardial infarction. *Ann Noninvasive Electrocardiol*. 2010 Apr;15(2):130–137. https://doi.org/10.1111/j.1542-474x.2010.003653.x.
34. King JH, Huang CL, Fraser JA. Determinants of myocardial conduction velocity: implications for arrhythmogenesis. *Front Physiol*. 2013;4:154.
35. De Groot JR, Coronel R. Acute ischemia-induced gap junctional uncoupling and arrhythmogenesis. *Cardiovasc Res*. 2004;62(2):323–334.
36. Chew DS, Wilton SB, Kavanagh K, et al. Fragmented QRS complexes after acute myocardial infarction are independently associated with unfavorable left ventricular remodeling. *J Electrocardiol*. 2017. https://doi.org/10.1016/j.jelectrocard.2018.04.004.

37. Tangwiwat C, Kaolawanich Y, Krittayaphong R. Electrocardiographic predictors of myocardial fibrosis and apical hypertrophic cardiomyopathy. *Ann Noninvasive Electrocardiol*. 2018;e12612. https://doi.org/10.1111/anec.12612.
38. Kanjanahattakij N, Rattanawong P, Riangwiwat T, et al. Fragmented QRS and mortality in patients undergoing percutaneous intervention for ST-elevation myocardial infarction: systematic review and meta-analysis. *Ann Noninvasive Electrocardiol*. 2018;e12567. https://doi.org/10.1111/anec.12567.
39. Gungor B, Ozcan KS, Karatas MB, Sahin I, Ozturk R, Bolca O. Prognostic value of QRS fragmentation in patients with acute myocardial infarction: a meta-analysis. *Ann Noninvasive Electrocardiol*. 2016;21(6):604–612. https://doi.org/10.1111/anec.12357.
40. DinakrismaAA Wijaya IP, Nasution SA, Dewiasty E. The role of fragmented QRS (fQRS) as A predictor of major adverse cardiac event within 30 days in acute coronary syndrome patients: a retrospective cohort study. *Acta Med Indones - Indones J Intern Med.* 2019;51(1):3–9.