



## Original Article

# “Incidence, clinical and angiographic characteristics, management and outcomes of coronary artery perforation at a high volume cardiac care center during percutaneous coronary intervention”



Chetana Krishnegowda<sup>a,\*</sup>, Beerasha Puttegowda<sup>b</sup>, Santhosh Krishnappa<sup>a</sup>,  
Rajiv Ananthakrishna<sup>b</sup>, Nagesh C. Mahadevappa<sup>b</sup>, Sadananda K. Siddegowda<sup>a</sup>,  
Raghu T. Ramegowda<sup>b</sup>, Cholenahally N. Manjunath<sup>b</sup>

<sup>a</sup> Department of Cardiology, Sri Jayadeva Institute of Cardiovascular Sciences and Research, Mysore Branch, India

<sup>b</sup> Department of Cardiology, Sri Jayadeva Institute of Cardiovascular Sciences and Research, Bangalore, India

## ARTICLE INFO

## Article history:

Received 7 April 2020

Accepted 7 July 2020

Available online 17 July 2020

## Keywords:

Cardiac tamponade

Coronary artery perforation

Covered stent

Percutaneous coronary interventions

Pericardiocentesis

## ABSTRACT

**Aims:** To study the incidence, clinical and angiographic characteristics, management and outcomes of coronary artery perforation (CAP) during percutaneous coronary intervention (PCI) at a high volume center in South-east Asia.

**Methods:** Data from patients who had CAP during PCI from January 2016 to December 2019 at our center were collected. Clinical features, angiographic and procedural characteristics, their management and outcomes were analyzed retrospectively.

**Results:** A total of 40,696 patients underwent PCI during the study period and the incidence of CAP was 0.13% (n = 51). Mean age was 60.0 ± 10.8 years and 69% were males. CAP cases involved complex type B2/C lesions in 73%, calcified lesions in 58%, and chronic total occlusions in 25%. Majority of patients presented as acute coronary syndrome (65%) and STEMI was the most frequent indication for PCI (33%). Most of the CAPs were Ellis type II (33%) and III (55%). CAP most frequently occurred during post dilation (n = 20) and wire manipulation (n = 17). Majority were treated by prolonged balloon inflation (53%) and covered stents (33%). Pericardiocentesis was required in 19 patients to alleviate tamponade. In one patient coil embolisation was done and two patients required bail-out emergency cardiac surgery. Peri-procedural myocardial infarction occurred in 6% and in-hospital mortality was 10%. All-cause mortality accrued to 14% at 30 days and 16% at 6 months.

**Conclusion:** Although incidence of CAP in contemporary interventional practice remains low, the morbidity and mortality are considerable. Early recognition and management strategies tailored to the severity of perforation play a key role in achieving better outcomes.

© 2020 Cardiological Society of India. Published by Elsevier B.V. This is an open access article under the CC BY-NC-ND license (<http://creativecommons.org/licenses/by-nc-nd/4.0/>).

## 1. Introduction

Coronary artery perforation (CAP) is a rare but potentially life-threatening complication of percutaneous coronary intervention (PCI). The reported incidence of CAP is 0.1–0.71% with a mortality ranging from 7 to 17%.<sup>1–8</sup> The management of CAP is often challenging and in high grade perforations, emergency surgery has been the standard treatment. In recent times, with the advances in

interventional devices like covered stents and microcoils, most of the cases are now being efficiently managed percutaneously. Data on CAP in Indian population is limited to small case series and anecdotal reports so far. Therefore, the objective of the present study was to report our experience with CAP over a 4-year period with respect to incidence, clinical and angiographic characteristics, management strategies and outcome at one of the largest cardiac care centers in South-east Asia.

## 2. Methods

This study was a retrospective analysis of the PCI data from our center between January 2016 and December 2019. During this

\* Corresponding author. Sri Jayadeva Institute of Cardiovascular Sciences and Research, Mysore Branch, KRS Road, Kumbara Koppalu, Mysore, 570016, India.  
E-mail address: [chetana88@gmail.com](mailto:chetana88@gmail.com) (C. Krishnegowda).

period, patients who had CAP during PCI were identified by angiographic review. Clinical, angiographic and procedural characteristics, management of CAP and outcome were analyzed. CAPs were categorized using Ellis classification into types I, II, III and III CS (cavity spilling) as well as modified Ellis classification by EuroPCR team into types I, II, III, IV and V.<sup>9,10</sup> Lesion type was classified according to the ACC/AHA classification and angiographic characteristics of lesions such as calcification, tortuosity, chronic total occlusion and lesion length were registered.<sup>11</sup> Adverse in-hospital events including acute stent thrombosis (ST), reinfarction, need for urgent coronary artery bypass grafting (CABG) and death were recorded.<sup>12,13</sup> All patients were followed up for 6 months at regular intervals with hospital outpatient visits or telephone interviews. Those with evidence of moderate/severe ischemia on noninvasive tests underwent further angiographic evaluation. Long term outcomes in terms of ST, in-stent restenosis (ISR), target vessel revascularization (TVR), target lesion revascularization (TLR), myocardial infarction (MI), and death from any cause were registered. Major adverse cardiac event (MACE) was defined as a combination of all cause mortality, MI, TLR, TVR, and need for CABG. The study conformed to widely accepted ethical principles guiding human research (such as the Declaration of Helsinki) and was approved by a local ethics committee.

### 3. Results

During the study period, a total of 40,696 patients underwent PCI, of which 51 (0.13%) were complicated by CAP. The baseline clinical and procedural characteristics are shown in Table 1 and Table 2.

**Table 1**  
Baseline clinical characteristics of the CAP patients.

Patient characteristics	Result (n = 51)
Mean age, years	60.0 ± 10.8
Male sex	35 (69)
Known IHD	
Prior MI	2 (4)
Prior CABG	3 (6)
Prior PCI	3 (6)
Cardiovascular risk factors	
Diabetes mellitus	28 (55)
Hypertension	23 (45)
Dyslipidemia	24 (47)
Current smoker	26 (51)
Family h/o coronary artery disease	9 (18)
Renal dysfunction (creatinine>200umol/l)	3 (6)
Ejection fraction	48.2 ± 6.8
Multivessel disease	25 (49)
Indication for PCI	
STEMI	17 (33)
NSTEMI	16 (31)
Stable angina	12 (24)
Ischemic heart failure	4 (8)
Thrombolysis within 24 h	15 (29)
Urgent/emergency procedure	5 (10)
Antiplatelet therapy	
Clopidogrel	22 (43)
Prasugrel	7 (14)
Ticagrelor	12 (24)
Glycoprotein IIb/IIIa inhibitor	2 (4)
Proportion of DES usage	34 (67)

CABG= Coronary Artery Bypass Graft; IHD= Ischemic Heart Disease; MI = Myocardial Infarction; NSTEMI= Non ST Elevation Myocardial Infarction PCI= Percutaneous Coronary Intervention; STEMI= ST Elevation Myocardial Infarction. Data presented as absolute numbers and percentages or mean ± SD.

**Table 2**  
Procedural characteristics of the CAP patients.

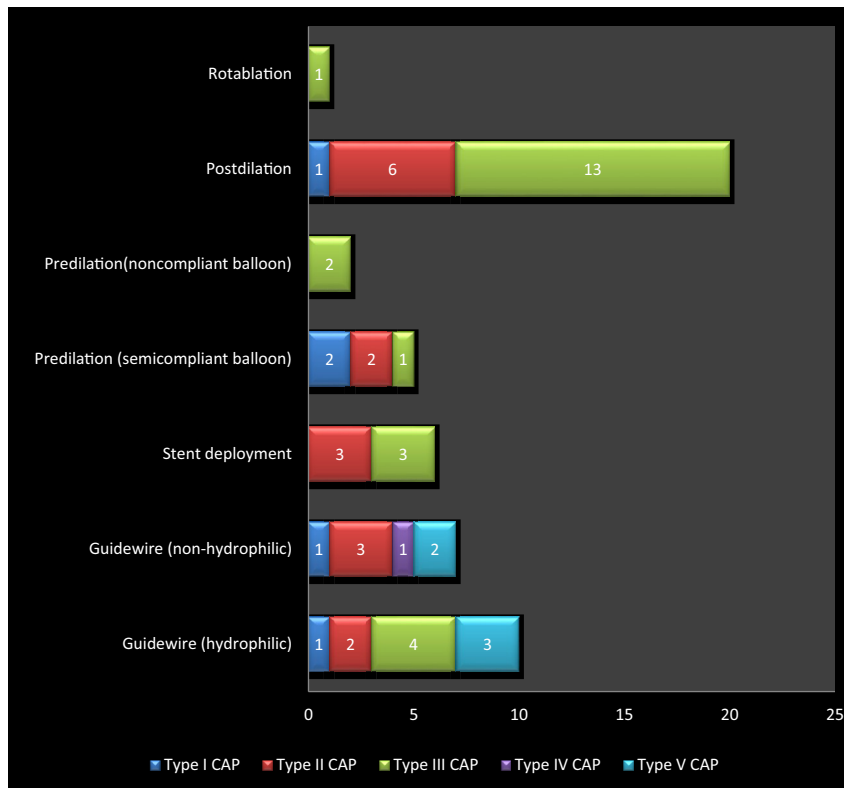
	Result (n = 51)
<b>Treated Vessel</b>	
Left main	0
Left anterior descending	17 (33)
Diagonal	3 (6)
Ramus	1 (2)
Circumflex	11 (22)
Right coronary artery	18 (35)
Saphenous vein graft	1 (2)
<b>Lesion location</b>	
Ostial	1 (2)
Proximal	22 (43)
Mid	30 (59)
Distal	5 (10)
<b>Lesion complexity and vessel morphology</b>	
A	6 (12)
B1	8 (16)
B2	11 (22)
C	26 (51)
Lesion length >20 mm	34 (67)
Vessel size	
Mean (mm)	2.8 ± 0.5
<2.5 mm	14 (27)
Moderate/severe calcification	30 (58)
Significant tortuosity >90°	16 (31)
Chronic total occlusion	13 (25)
In-stent restenosis	0
<b>Perforation severity (Ellis classification)</b>	
I	9 (18)
II	17 (33)
III	24 (47)
III CS	1 (2)
<b>Perforation severity (EuroPCR classification)</b>	
I	5 (10)
II	16 (31)
III	24 (47)
IV	1 (2)
V	5 (10)

CS= Cavity spilling.

Data presented as absolute numbers and percentages or mean ± SD.

#### 3.1. Baseline clinical and procedural characteristics

Mean age of the patients was 60.0 ± 10.8 years and males constituted 69%. The proportion of patients with an acute coronary syndrome (ACS) background was 65% of which, 17 cases presented with ST elevation myocardial infarction (STEMI) and 16 with non ST-elevation myocardial infarction (NSTEMI). CAP occurred during primary PCI and rescue PCI in 2 and 3 patients respectively. Cardiovascular risk factors such as diabetes, smoking and hypertension were present in 55%, 51% and 45% respectively. Renal dysfunction was observed in 6% of patients and multi vessel disease was observed in 49%. Treated lesions were classified as ACC/AHA type B2 or C in 73%, and angiographic calcifications were present in 58% of patients. Overall, 25% of the CAP cases involved chronic total occlusions (CTO). Mean vessel diameter was 2.8 ± 0.5 mm and small vessels were involved in 27% of CAP cases. Diffuse disease was present in 67% and significant tortuosity was present in 31% of patients. Among the 51 patients in whom CAP was recognized angiographically, most CAPs were Ellis type II (33%) and III (55%). CAP most frequently occurred during post dilation (39%). Guide-wire manipulation, predilation, stent deployment and rotablation attributed to CAP in 33%, 14%, 12% and 2% respectively (Graph 1). Majority of the patients were on dual antiplatelet therapy including aspirin and clopidogrel (43%). Ticagrelor and prasugrel usage was seen in 12 and 7 patients each. In addition, 2 patients received glycoprotein IIb/IIIa inhibitor (GPI) tirofiban.



**Graph 1.** Mechanisms responsible for CAP.

### 3.2. Management of CAP

Of 51 cases of CAP, treatment was conservative in twelve. Prolonged balloon inflation was done in majority of type II (50%) and type III CAP (63%) at low pressures of 4–6 atm for an average duration of 10 min. In all hemodynamically unstable patients, insertion of a pericardial drain to relieve tamponade was promptly performed (37%). Covered stent implantation was required to seal the perforation in 67% of type III CAP. Treatment was multimodal in 20 cases (39%). Most of the distal wire-tip perforations (EuroPCR type V) were managed conservatively except one case where microcoil embolization of the diagonal artery was performed. Out of the 51 cases, only 2 cases were referred for emergency surgery.

### 3.3. Clinical outcomes

The outcomes of CAP in our patients varied considerably with the type of perforation. Patients who sustained type I or II CAP had an overall good prognosis, with 5% in-hospital mortality and 9% had cardiac tamponade. In contrast, patients with type III perforations had 14% in-hospital mortality, and 66.6% of them had cardiac tamponade. Overall, in-hospital mortality of patients complicated with CAP was 10% and periprocedural myocardial infarction occurred in 6% of the patients including one case of acute ST. On follow up of CAP patients, 47% remained asymptomatic at 6 months. 6 patients underwent TVR, 2 underwent TLR while 1 patient underwent CABG in the follow up period. We had one patient with early ST and one patient with late ST. All cause mortality was 14% and 16% at 30 days and at 6 months respectively. Seven patients were lost to follow up (Table 3). Among 51 CAP cases, right coronary artery (RCA) was the most common vessel involved and contributed to majority of type III CAP (42%) with two fatal outcomes. CAP of left anterior descending (LAD) artery had the highest procedural

success rate of 76%. We had one case each involving saphenous vein graft (SVG) and ramus and both were fatal. Distal type V CAP predominantly occurred in the diagonal artery (3/5) and none had adverse outcomes.

## 4. Discussion

### 4.1. Incidence and mortality rate

The present study represents the real-world experience of CAP complicating routine PCI at a high volume tertiary center in the contemporary DES era. A total of 40,696 balloon angioplasties were

**Table 3**  
Immediate and long term outcomes of the CAP patients.

	Result (n = 51)
<b>In-hospital events</b>	
Reinfarction	2 (4)
Sidebranch occlusion	6 (12)
Acute stent thrombosis	1 (2)
Death	5 (10)
<b>Long term outcome during follow-up period (n = 44)</b>	
Unstable angina (CCS IV)	3
Stable angina (CCS I-III)	8
Asymptomatic (CCS 0)	24 (47)
Myocardial infarction	2 (4)
Stent thrombosis	1 (2)
Target lesion revascularization	2 (4)
Target vessel revascularization	6 (12)
Need for CABG	1 (2)
<b>All cause mortality</b>	
At 30-days	7 (14)
At 6 months	8 (16)

CABG= Coronary Artery Bypass Graft; CCS= Canadian Cardiovascular society. Data presented as absolute numbers and percentages.

**Table 4**

Type of perforation, treatment modalities and procedural outcomes of CAP with respect to the vessel involved.

Vessel involved	EURO PCR type of CAP					Treatment modality						Procedural outcome		
	I	II	III	IV	V	Conservative	Prolonged balloon inflation	Pericardiocentesis	Covered stent	Coiling	Emergency surgery	Successful	Abandoned	Mortality
LAD (n = 17)	2	7	7	0	1	4	10	7	6	0	1	13	3	1
RCA (n = 18)	3	5	10	0	0	4	9	7	7	0	1	11	5	2
LCX (n = 11)	0	4	5	1	1	3	8	4	2	0	0	8	3	0
Diagonal (n = 3)	0	0	0	0	3	1	1	0	0	1	0	2	1	0
SVG (n = 1)	0	0	1	0	0	0	0	0	1	0	0	0	0	1
Ramus (n = 1)	0	0	1	0	0	0	1	1	1	0	0	0	0	1
Total	5 (10)	16 (31)	24 (47)	1 (2)	5 (10)	14 (27)	27 (53)	19 (37)	17 (33)	1 (2)	2 (4)	34 (67)	12 (24)	5 (10)

LAD = Left Anterior Descending; LCX = Left Circumflex; RCA = Right Coronary Artery; SVG = Saphenous vein graft.

Data presented as absolute numbers and percentages.

done in our institute during this period, and CAP were observed in 0.13% (n = 51) with in-hospital mortality rate of 10% (n = 5), comparable to that of previous registries (Table 5).

#### 4.2. Procedural characteristics

The independent predictors of CAP reported so far are age, female gender, angiographic complex lesions, CTO, calcification, and use of cutting balloon or rotational atherectomy.<sup>2,3,6,8,9,15</sup> In our cohort, CAP occurred more frequently in complex lesions (type B2/C), calcified vessels and CTO interventions. RCA was the most frequent artery associated with CAP, consistent with previous studies.<sup>3,15</sup> The inherent long course and tortuosity of the vessel is probably the reason for increased risk of CAP in RCA interventions. In addition, CAPs of RCA had lesser procedural success compared to that of LAD and LCX in our cohort.<sup>Table 4</sup>

Interestingly, the most common mechanism responsible for CAP in the present study was post dilation (39%), and guidewire advancement was the second most common mechanism (33%). Unlike previous registries in which guidewire advancement was the commonest cause for perforation, the higher incidence of CAP during post dilation in the present study is a reflection of the significantly high number of calcific lesions treated in our cohort (58%). The tendency to postdilute resistant lesions aggressively at higher pressures may have resulted in CAP. A large analysis from the British database observed that the use of cutting balloon avoided inadvertent post dilation and was indeed protective against perforation in their patient subset.<sup>3</sup> In the context of overall lesser

use of atheroablative devices at our center, suboptimal lesion preparation is the most possible explanation for high likelihood of CAP during post dilation in our cohort. In addition, two patients in our cohort had CAP due to balloon: artery ratio >1.2 and in one patient pinhole rupture of post dilation balloon was responsible for CAP.

In the current era of interventional practice, it is proven beyond doubt that intravascular imaging like optical coherence tomography (OCT) and intravascular ultrasound (IVUS) provide clear knowledge of lesion characteristics and the extent of calcification which helps in the selection of appropriate atheroablative methods either rotablation or cutting balloon prior to stenting as well as stent optimization, thus contributing to superior outcomes in complex interventions. These imaging modalities were however, underutilized in our study as they were introduced almost towards the end of the study period at our center. Therefore, imaging may also play a significant role in the reduction of incidence of CAP in the future and needs further assessment.

Our data revealed a relatively lesser incidence of guidewire induced perforations which can be explained by the fact that most of the lesions were attempted with non hydrophilic workhorse guidewires in our institute and the use of hydrophilic wires was uncommon. A recent study by Lemmert et al. reported an overall incidence of CAP in 0.71% of cases and wire induced perforations contributed to 61.5% of them. However, it is important to note that non-workhorse guidewires were used in majority (74.5%) of their cases.<sup>8</sup>

**Table 5**

Comparison of our study with previous published series of CAP.

Author	No. of cases	Period of study	Incidence	Grade II and above (incidence [%])	Mortality	Risk factors for perforation
Ellis et al 1994 <sup>10</sup>	12,900	1990–1991	62 (0.5%)	47 (0.4%)	41%	Women, age
Gruberg et al 2000 <sup>14</sup>	30,746	1990–1999	88 (0.29%)	Not reported	10%	Women, atheroablative devices
Dippel et al 2001 <sup>2</sup>	6214	1995–1999	36 (0.58%)	36 (0.58%)	11.1%	Atheroablative devices, heart failure
Gunning et al 2002 <sup>5</sup>	6245	1995–2001	52 (0.8%)	Not reported	11.5%	Not tested
Fasseas et al 2004 <sup>6</sup>	16,298	1990–2001	95 (0.58%)	78 (0.48%)	7.4%	Atheroablative devices, women, type C lesion, CABG
Javaid et al 2006 <sup>4</sup>	38,559	1996–2005	72 (0.19%)	58 (0.15%)	17%	Not tested
Shimony et al 2009 <sup>16</sup>	9568	2001–2008	57 (0.59%)	50 (0.52%)	7%	Age, hypertension, CTO, calcification, CABG, ACS, RCA, femoral approach
Ben-Gal et al 2010 <sup>17</sup>	13,466	2004–2008	33 (0.25%)	26 (0.19%)	12%	Not tested
Kinniard et al 2016 <sup>3</sup>	527,121	2006–2013	1762 (0.33%)	Not reported	8%	Age, female sex, CTO, atherectomy, renal impairment, previous MI, RCA, LMCA
Lemmert et al 2017 <sup>8</sup>	21,212	2005–2016	150 (0.71%)	101 (0.47%)	8%	Complex lesions (type B2/C), CTO, nonworkhorse guidewires
Our study	40,696	2016–2019	51 (0.13%)	42 (0.10%)	10%	Complex lesions (type B2/C), calcification, CTO, ACS, RCA

ACS = Acute Coronary Syndrome; CTO = Chronic Total Occlusion; LMCA = Left Main Coronary Artery; MI = Myocardial Infarction; RCA = Right Coronary Artery.

Data presented as absolute numbers and percentages.

**Table 6**  
Details of the fatal perforation cases.

	Age	Sex	Vessel	Clinical syndrome	Lysis/GPI within 24 h	Device responsible	Treatment	Perforation sealed	Cause of death
1	63	F	RCA	Unstable angina	No	Guidewire	Pericardiocentesis + balloon inflation	Yes	Multiorgan failure
2	78	M	LAD	Stable angina	No	Postdilation balloon	Pericardiocentesis + balloon inflation	No	Cardiogenic shock
3	55	M	SVG	Unstable angina	No	Stent	Pericardiocentesis + covered stent	Yes	Multiorgan failure
4	38	F	RCA	STEMI	No	Stent	Pericardiocentesis + balloon inflation	No	Cardiogenic shock
5	45	M	Ramus	Unstable angina	No	Postdilation balloon	Pericardiocentesis + balloon inflation + covered stent	No	Multiorgan failure

GPI = Glycoprotein inhibitors; LAD = Left Anterior Descending; LCX = Left Circumflex; RCA = Right Coronary Artery; SVG = Saphenous vein graft; STEMI = ST Elevation Myocardial Infarction.

#### 4.3. Management protocol

All CAP cases of Ellis type I and majority of type II without significant coronary extravasation were managed conservatively with close patient monitoring and serial echocardiography in the first 24 h (27%). Immediate prolonged balloon inflation was done in 53% of our CAP cases and balloon inflation alone was sufficient to seal the perforation in majority of Ellis type I and II CAP (88%). Two cases of type II CAP required pericardiocentesis in addition to prolonged balloon inflation. Overall, the incidence of cardiac tamponade requiring acute pericardiocentesis in our patients was 37% and 17 out of 19 cases were type III CAP. Compared to our data, clinical tamponade occurred in 48%,<sup>8</sup> 28.6%<sup>17</sup> and 14%<sup>3</sup> in large contemporary registries and was somewhat proportionate to the prevalence of CTO in each cohort (31.3%,<sup>8</sup> 28.6%<sup>17</sup> and 18%<sup>3</sup>), which is reflective of a less aggressive approach to CTOs in our center.

The treatment protocol for large perforations (Ellis type III) at our center, in general, was initial stabilization with pericardial drain insertion and low pressure balloon tamponade of the perforated vessel followed by covered stent insertion. In a previous analysis, covered stent insertion was performed in 46.4% of type III CAPs, compared to 67% in the present study. This is in correlation with the fact that 32.1% of CAPs were within small vessels in their analysis compared to 14% in ours.<sup>17</sup> However, the success rate of covered stents in achieving hemostasis was remarkably high in both the analyses.

Unfortunately PTFE-covered stents are known to be bulky and difficult to deliver, particularly in tortuous and calcified vessels. In our series, out of the five fatalities the operator was unable to deliver covered stent to the perforated segment (mid RCA) in one patient. Advent of novel pericardial-covered stent (Over and Under®) with improved deliverability and safety profile has influenced the procedural outcomes in other parts of the world, and are now available in a variety of sizes.<sup>18,19</sup> The use of autologous vein-covered stents has been reported in some studies, but harvesting the graft and mounting onto a metallic stent appear to be time-consuming and therefore not a feasible option in extremely urgent cases.<sup>20</sup> Another major concern of covered stents is the associated risk of ST and a recent study of CAP over a 19-year period mentioned that patients with covered stent insertion have a 10-fold higher risk of ST at 5 years warranting close follow up of these patients.<sup>21</sup> The incidence of ST in our analysis was however considerably low at 4%, in the context of covered stent deployment in 33% of our patients.

Reversal of heparin is not a common practice at our institute as routine administration of protamine is considered unsafe and can be detrimental. The authors of a retrospective analysis from UK were also of a similar opinion that one has to weigh the benefit of

reversal of heparin with the risk of acute vessel thrombosis and anaphylaxis in each individual case and use protamine cautiously.<sup>22</sup> Although protamine was administered in two out of 51 cases in our cohort, the outcomes did not differ much compared to a previous study where protamine was considered mandatory if heparin or glycoprotein inhibitors had been administered.<sup>17</sup>

Most of the distal perforations (type V) were managed conservatively in our study except one patient treated by microcoil embolization. Majority of wire-exit perforations were induced by hydrophilic wire advancement in CTOs in previous case series.<sup>23,24</sup> In our study, CTO was noted in 38% of guidewire induced perforations and hydrophilic guidewires were responsible for 3 out of 5 wire-exit perforations.

There has been tremendous advancement in the treatment of distal perforations in the recent years, microcoil embolization being one of the most feasible and frequently used methods for treatment of distal perforations.<sup>25–27</sup> The size of the coil should be 1.5 times the targeted vessel caliber as a coil that is too big may dislodge in the proximal segment of the artery and one too small may embolize distally. These coils may be delivered through the guide catheter or more precisely to the distal segment through microcatheter. Our experience with coil embolisation was however limited to just one case.

Other embolization materials like microspheres, clotted blood from the patient, thrombin, two component fibrin-glue, collagen, transcatheter subcutaneous tissue delivery, cyanoacrylate liquid glue, denatured alcohol, or polyvinyl alcohol particles and use of a local drug delivery catheter have been described in anecdotal reports and their safety needs to be verified in large studies.<sup>28–37</sup> Major advantages of using autologous blood clots and fat are easy availability, no cost and biocompatibility issues, and will get lysed automatically later. These blood clots are usually mixed with contrast media or saline, and then injected to the particular site. Main drawback of using embolic materials is that they result in permanent occlusion of the vessel beyond the site of deployment and subsequent infarction. Additionally, foreign body reaction to absorbable gelatin sponge has been noted leading to granulomatous arteritis and coronary occlusion. Gelatin sponge had a stronger reaction when compared to microcoils.<sup>38</sup>

#### 4.4. Outcome

A large proportion (65%) of our CAP patients presented with ACS. 29% had been thrombolysed and the in-hospital MACE and mortality was 27% and 10% respectively, comparable to other CAP studies.<sup>3,8,15</sup> Importantly, periprocedural MI was much lower compared to a previous registry (34% vs 6%), a likely reflection of



the judicious use of protamine and continuation of dual antiplatelet drugs in majority of our patients owing to their ACS background.<sup>8</sup>

Ellis type III perforation had the poorest prognosis and contributed to high mortality and morbidity in our study which is in line with the recent literature on outcomes of CAP.<sup>3,8,17</sup> Covered stents, undoubtedly, had the highest potential to seal large perforations (88.2%) and their availability in the catheterization laboratory was the major reason for most of the patients managed effectively without the need of emergency cardiac surgery in the current study. CAP cases requiring surgical intervention in our cohort was remarkably low (4%) when compared to other cohorts where 5.3% and 3.7% of patients underwent bail-out CABG.<sup>8,17</sup> In most of our fatal CAPs, the major contributor of death was multi-organ dysfunction as a result of prolonged hypotension, and in two of them massive bleeding from perforated vessel despite covered stent insertion was the cause of mortality (Table 6).

## 5. Study limitations

The present study has some limitations: 1) it was a retrospective study with inherent limitations; 2) our experience of CAP related to atheroablative devices was limited due to the overall lesser usage of these devices at our center; 3) invasive imaging such as IVUS and OCT were not routinely performed at our center during the study period; 4) angiographic follow up was not done in all patients, however they were clinically followed up on a regular basis.

## 6. Conclusion

CAP is a major complication of PCI with significant morbidity and mortality. The incidence of CAP is similar to previously published studies. The present study reflects the contemporary practices and is concordant with the fact that most of the CAPs can be efficiently managed by percutaneous interventions. Prolonged low-pressure balloon inflation is sufficient to seal most of the mild perforations without cardiac tamponade whereas in the event of a high-grade perforation, covered stent has proven to be the most useful, lifesaving device in current interventional practice. The bulky profile and inherent risk of thrombogenicity with covered stents is a major setback. Advancement in covered stent technology and novel therapeutic options for distal CAPs may facilitate higher success rates in the treatment of perforation in future and requires further studies.

## 7. Impact on daily practice

The present study is reflective of the contemporary incidence, management trends and outcomes of CAP in the real world setting. Although CAP remains a rare complication, grade III CAP are still associated with a significant risk of mortality and poor acute and long term prognosis. Therefore, a structured approach and thorough knowledge of the latest treatment options available is necessary to tackle this major complication.

## Funding

None.

## Declaration of competing interest

The authors have no conflicts of interest to declare.

## Acknowledgements

We are grateful to all the staff of the catheterization laboratory, coronary care unit, and cardiac wards at Sri Jayadeva Institute of Cardiovascular Sciences and Research.

## References

- Ajluni SC, Glazier S, Blankenship L, et al. Perforations after percutaneous coronary interventions: clinical, angiographic, and therapeutic observations. *Cathet Cardiovasc Diagn.* 1994;32:206–212.
- Dippel EJ, Kereiakas DJ, Tramuta DA, et al. Coronary perforation during percutaneous coronary intervention in the era of abciximab platelet glycoprotein IIb/IIIa blockade: an algorithm for percutaneous management. *Cathet Cardiovasc Interv.* 2001;52:279–286.
- Kinnaird T, Kwok CS, Kontopantelis E, et al. Incidence, determinants, and outcomes of coronary perforation during percutaneous coronary intervention in the United Kingdom between 2006 and 2013. *Circ Cardiovasc Interv.* 2016;9, e003449.
- Javadi A, Buch AN, Satler LF, et al. Management and outcomes of coronary artery perforation during percutaneous coronary intervention. *Am J Cardiol.* 2006;98:911–914.
- Gunning MG, Williams IL, Jewitt DE, et al. Coronary artery perforation during percutaneous intervention: incidence and outcome. *Heart.* 2002;88:495–498.
- Fasseas P, Orford JL, Panetta CJ, et al. Incidence, correlates, management, and clinical outcome of coronary perforation: analysis of 16,298 procedures. *Am Heart J.* 2004;147:140–145.
- Kiernan TJ, Yan BP, Ruggiero N, et al. Coronary artery perforations in the contemporary interventional era. *J Interv Cardiol.* 2009;22:350–353.
- Lemmer ME, Bommel RJ, Diletti R, et al. Clinical characteristics and management of coronary artery perforations: a single-center 11-year experience and practical overview. *J Am Heart Assoc.* 2017;6, e007049.
- Ellis SG, Ajluni S, Arnold AZ, et al. Increased coronary perforation in the new device era: incidence, classification, management, and outcome. *Circulation.* 1994;90:2725–2730.
- Müller O, Windecker S, Cuisset T, et al. Management of two major complications in the cardiac catheterisation laboratory: the no-reflow phenomenon and coronary perforations. *Euro Intervention.* 2008;4:181–183.
- Ryan TJ, Faxon DP, Gunnar RM, et al. Guidelines for percutaneous transluminal coronary angioplasty. A report of the ACC/AHA task force on assessment of diagnostic and therapeutic cardiovascular procedures (subcommittee on percutaneous transluminal coronary angioplasty). *Circulation.* 1988;78:486–502.
- Thygesen K, Alpert JS, Jaffe AS, et al. ESC Scientific Document Group Fourth universal definition of myocardial infarction. *Eur Heart J.* 2019;40:237–269.
- Cutlip DE, Windecker S, Mehran R, et al. Clinical end points in coronary stent trials: a case for standardized definitions. *Circulation.* 2007;115:2344–2351.
- Gruberg L, Pinnow E, Flood R, et al. Incidence, management, and outcome of coronary artery perforation during percutaneous coronary intervention. *Am J Cardiol.* 2000;86:680–682.
- Shimony A, Van Zahger D, Straten M, et al. Incidence, risk factors, management and outcomes of coronary artery perforation during percutaneous coronary intervention. *Am J Cardiol.* 2009;104:1674–1677.
- Ben-Gal Y, Weisz G, Collins MB, et al. Dual catheter technique for the treatment of severe coronary artery perforations. *Cathet Cardiovasc Diagn.* 2010;75:708–712.
- Al-Lamee AR, Ielasi A, Latib A, et al. Incidence, predictors, management, immediate and long-term outcomes following grade III coronary perforation. *JACC Cardiovasc Interv.* 2011;4:87–95.
- Jokhi PP, McKenzie DB, O’Kane P. Use of a novel pericardial covered stent to seal an iatrogenic coronary perforation. *J Invasive Cardiol.* 2009;21:187–190.
- Chen S, Lotan C, Jaffe R, et al. Pericardial covered stent for coronary perforations. *Cathet Cardiovasc Interv.* 2015;86:400–404.
- Stefanadis C, Toutouzas K, Tsiamb E, et al. Stents covered by autologous venous grafts: feasibility and immediate and long-term results. *Am Heart J.* 2000;139(3):437–445.
- Ford T, Morrow A, Adamson C, et al. Coronary artery perforations: glasgow natural history study of covered stent coronary interventions (GNOCCI) study. *JACC (J Am Coll Cardiol).* 2019;74:13.
- Hendry C, Fraser D, Eichhofer J, et al. Coronary perforation in the drug-eluting stent era: incidence, risk factors, management and outcome: the UK experience. *Euro Intervention.* 2012;7:79–86.
- Teis A, Fernández-Nofreñas E, Rodríguez-Leor O, et al. Coronary artery perforation by intracoronary guide wires: risk factors and clinical outcomes. *Rev Esp Cardiol.* 2010;63(6):730–734.
- Stathopoulos I, Panagopoulos G, Kossidas K, Jimenez M, Garratt K. Guidewire-induced coronary artery perforation and tamponade during PCI: in-hospital outcomes and impact on long-term survival. *J Invasive Cardiol.* 2014;26:371–376.
- Yeo KK, Rogers JH, Laird JR. Use of stent grafts and coils in vessel rupture and perforation. *J Interv Cardiol.* 2008;21(1):86–99.

26. Pershad A, Yarkoni A, Biglari D. Management of distal coronary perforations. *J Invasive Cardiol*. 2008;20(6):E187–E191.
27. Kim JH, Kim MK, Kim YJ, Park SM, Park KH, Choi YJ. Is a metallic microcoil really a permanent embolic agent for the management of distal guidewire-induced coronary artery perforation? *Korean Circ J*. 2011;41(8):474–478.
28. Meincke F, Kuck KH, Bergmann MW. Cardiac tamponade due to coronary perforation during percutaneous interventions successfully treated with microspheres. *Clin Res Cardiol*. 2014;103(4):325–327.
29. Politi L, Iaccarino D, Sangiorgi GM, Modena MG. Huge coronary perforation during percutaneous intervention sealed by injection of polyvinyl alcohol microspheres. *J Cardiovasc Med*. 2015;16(Suppl 2):S130–S132.
30. Fischell TA, Korban EH, Lauer MA. Successful treatment of distal coronary guidewire-induced perforation with balloon catheter delivery of intracoronary thrombin. *Cathet Cardiovasc Interv*. 2003;58(3):370–374.
31. Fischell TA, Moualla SK, Mannem SR. Intracoronary thrombin injection using a microcatheter to treat guidewire-induced coronary artery perforation. *Cardiovasc Revascularization Med*. 2011;12(5):329–333.
32. Goel PK. Delayed and repeated cardiac tamponade following microleak in RCA successfully treated with intraarterial sterile glue injection. *Cathet Cardiovasc Interv*. 2009;73(6):797–800.
33. Störger H, Ruef J. Closure of guide wire-induced coronary artery perforation with a two-component fibrin glue. *Cathet Cardiovasc Interv*. 2007;70(2):237–240.
34. Cordero H, Gupta N, Underwood PL, Gogte ST, Heuser RR. Intracoronary autologous blood to seal a coronary perforation. *Herz*. 2001;26(2):157–160.
35. George S, Cotton J, Wrigley B. Guidewire-induced coronary perforation successfully treated with subcutaneous fat embolisation: a simple technique available to all. *Cathet Cardiovasc Interv*. 2015;86(7):1186–1188.
36. Shemisa K, Karatasakis A, Brilakis ES. Management of guidewire-induced distal coronary perforation using autologous fat particles versus coil embolization. *Cathet Cardiovasc Interv*. 2017;89(2):253–258.
37. Aleong G, Jimenez-Quevedo P, Alfonso F. Collagen embolization for the successful treatment of a distal coronary artery perforation. *Cathet Cardiovasc Interv*. 2009;73(3):332–335.
38. Kawano H, Arakawa S, Satoh O, Matsumoto Y, Hayano M, Miyabara S. Foreign body granulomatous change from absorbable gelatin sponge and microcoil embolization after a guide wire-induced perforation in the distal coronary artery. *Intern Med*. 2010;49:1871–1874.